
TODAY'S LESSON:
HUMAN ANATOMY!!!
SWOFFORD '91

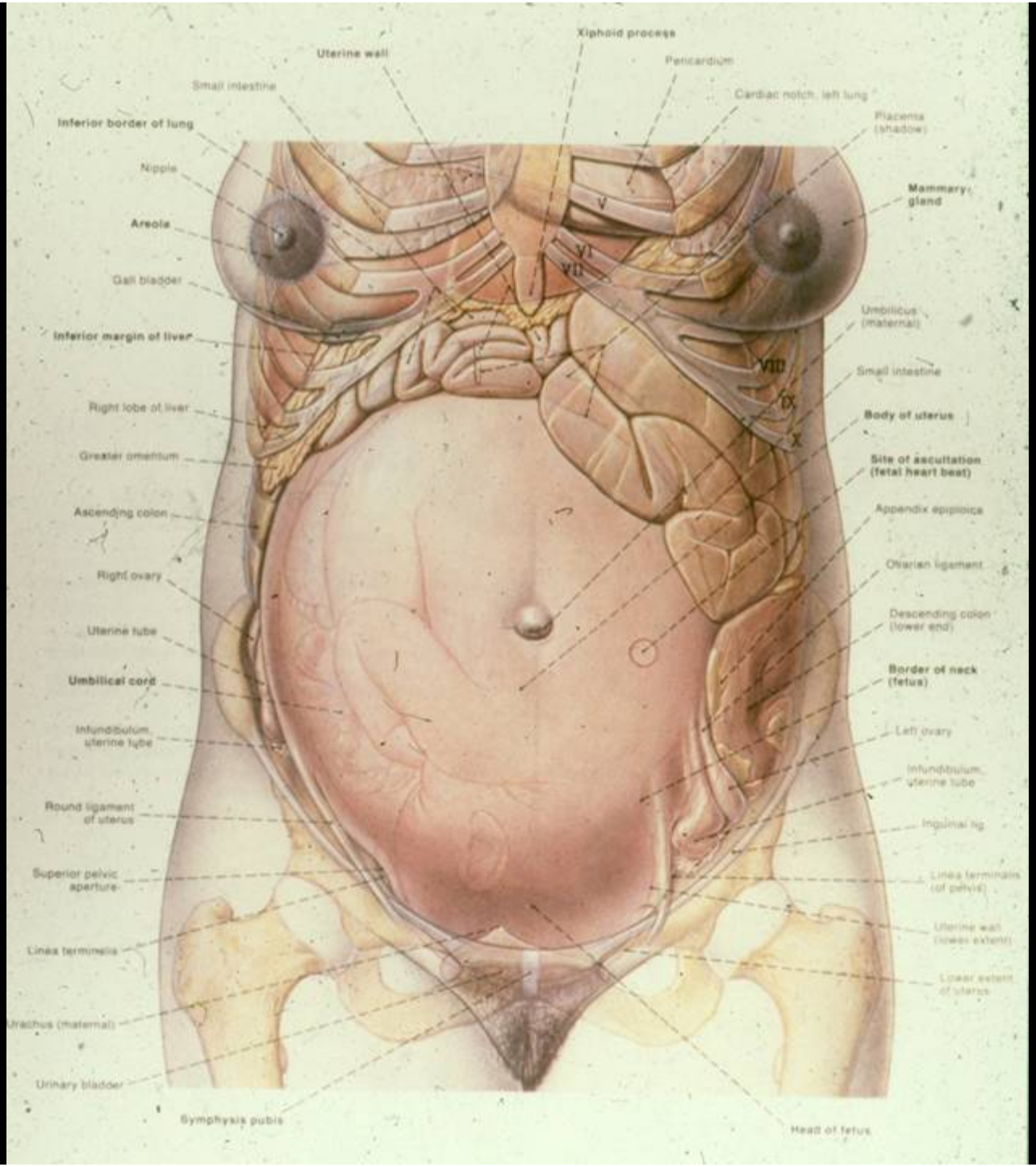
Xiphoid process
Uterine wall
Pericardium
Small intestine
Cardiac notch, left lung
Inferior border of lung
Placenta (shadow)
Nipple
Mammary gland
Areola
Gall bladder
Umbilicus (maternal)
Inferior margin of liver
Small intestine
Right lobe of liver
Body of uterus
Greater omentum
Site of auscultation (fetal heart beat)
Ascending colon
Appendix epiploica
Ovarian ligament
Right ovary
Descending colon (lower end)
Uterine tube
Border of neck (fetus)
Umbilical cord
Infundibulum uterine tube
Left ovary
Infundibulum uterine tube
Round ligament of uterus
Inguinal lig
Superior pelvic aperture
Linea terminalis (of pelvis)
Uterine wall (lower extent)
Linea terminalis
Lower extent of uterus
Urachus (maternal)
Urinary bladder
Symphysis pubis
Head of fetus

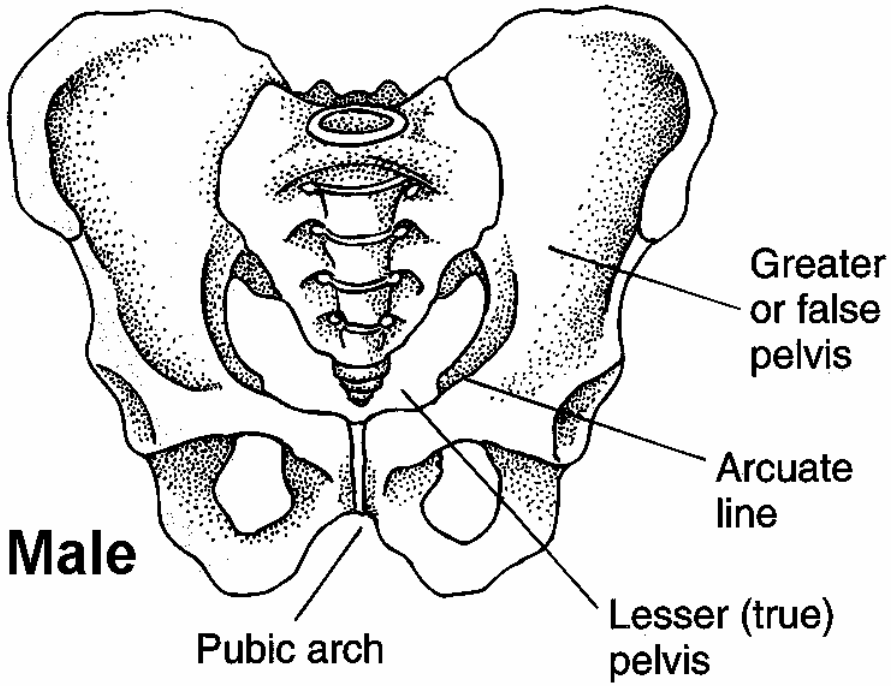
Greater
or false
pelvis
Arcuate
line
Male
Lesser (true)
pelvis
Pubic arch

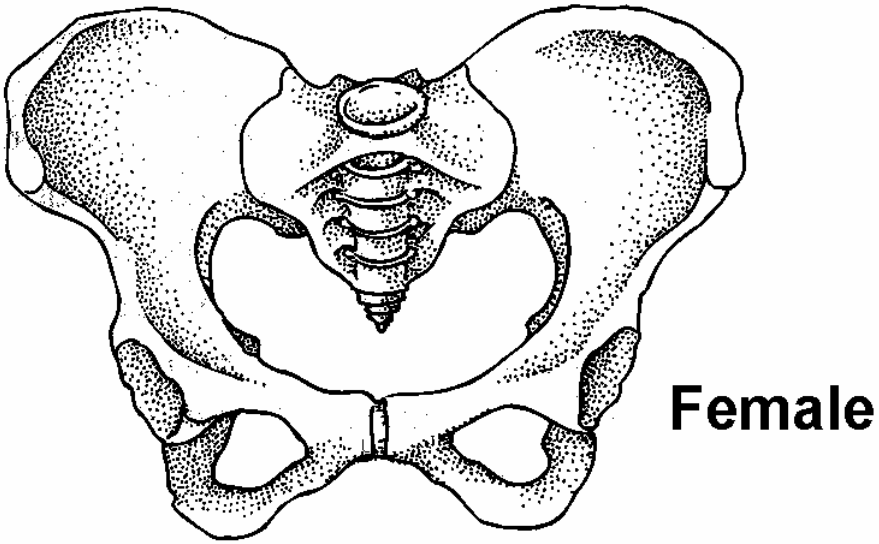
Female

CORPUS CARTOONUS

A. Maxillius Curvicus
B. Caninus Rectangularis
C. Mandible Malleable
D. Cranius Corporatus Symbolicus
E. Digitus Whimsicalus

Q. Cranius Imbicilicus
R. Spinous Rubber Hoseicus
S. Thoraxis Flexibilicus
T. Humourus

F. Ulnaris Elasticus
G. Olecranon Optionalis
H. Pelvis Squashenstretchicus
I. Femoris Speghetticus
J. Patella Invisibilicus

K. Tibialis and Wonderlandicus
L. Tarsus Farcicus
M. Carpalus Comicus
N. Radialis Bendicus
O. Dis-Knee Joint
P. Fairey Tale

U. Fibularis Bazaarus

ARTWORK FOR DISNEY ANIMATION TRAINING. NOT A PRODUCTION DRAWING.

MOUSE: (*Rodentus Celebritis*)

DOG:(*Caninus Gooficus*)

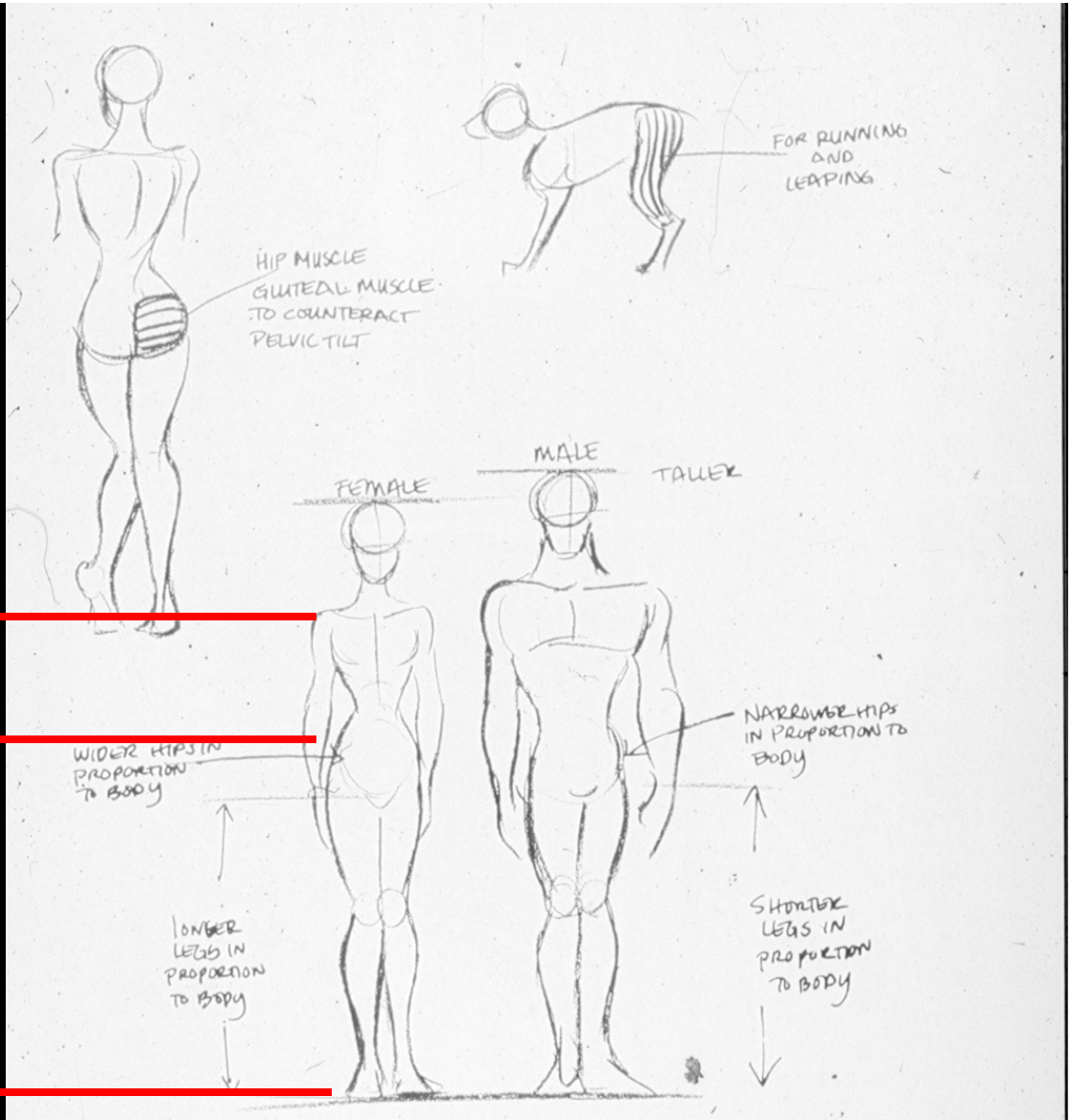

WHEN PERSON HITS PUBERTY → THEN BONE STOPS DEPOSITING
THEREFORE, IF PUBERTY IS DELAYED → THEN IS MORE BONIER-LOOKING
HEAVY BONED

MATURITY — TAKES A WHILE FOR BODY TO CATCH UP TO LEGS (IN GROWTH)
THEREFORE, WOMEN MATURE EARLIER → LONGER LEGS

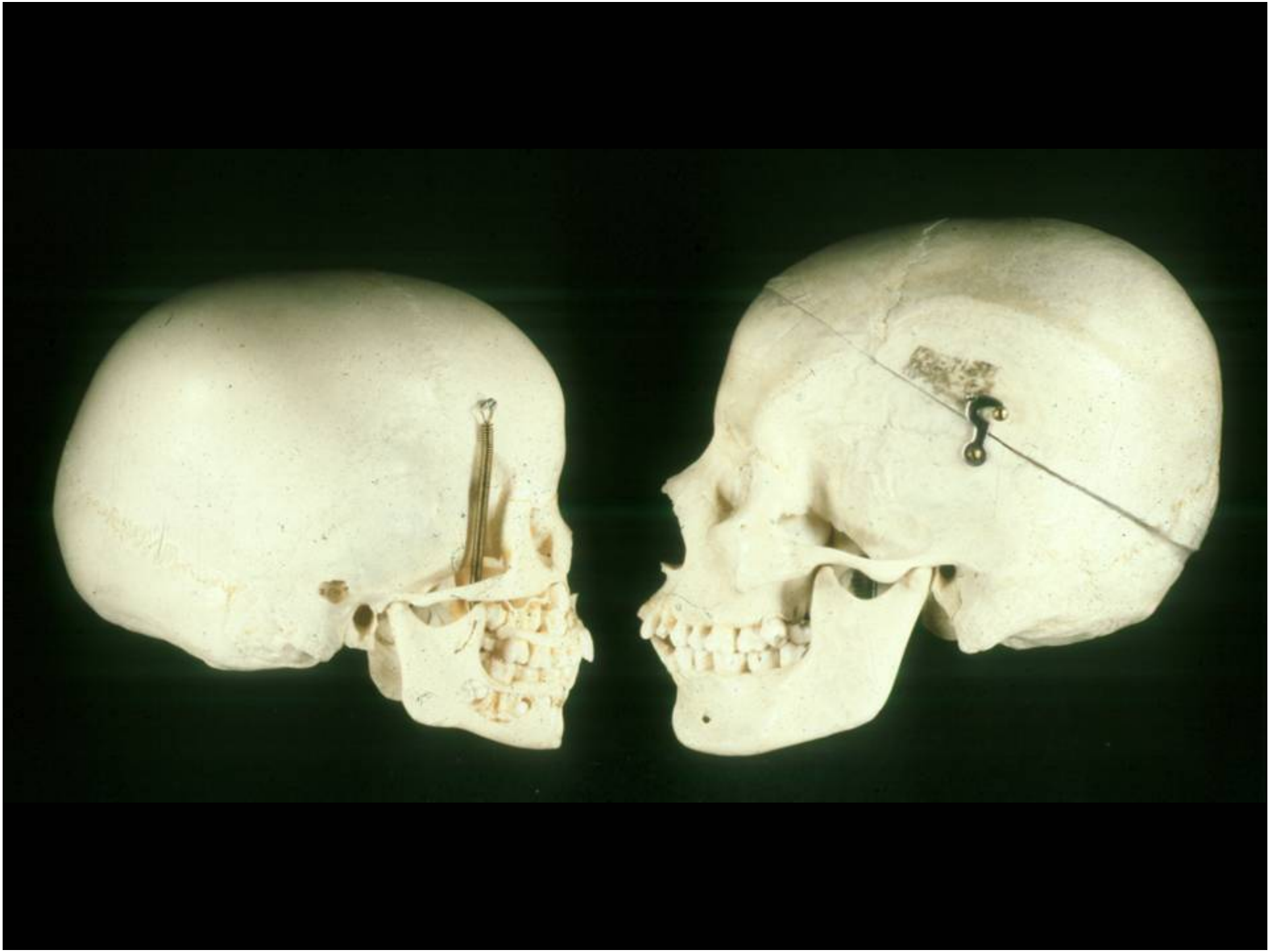


to
BETTI
THANKS FOR
BE INSPIRING
ECHIE!
3-24-94


To
STUART
THANKS FOR
THE GREAT LECTURE!
AND INSPIRING JAW LINE!
POCAHONTAS
3-24-94
- Colleen Kane

FEMALE

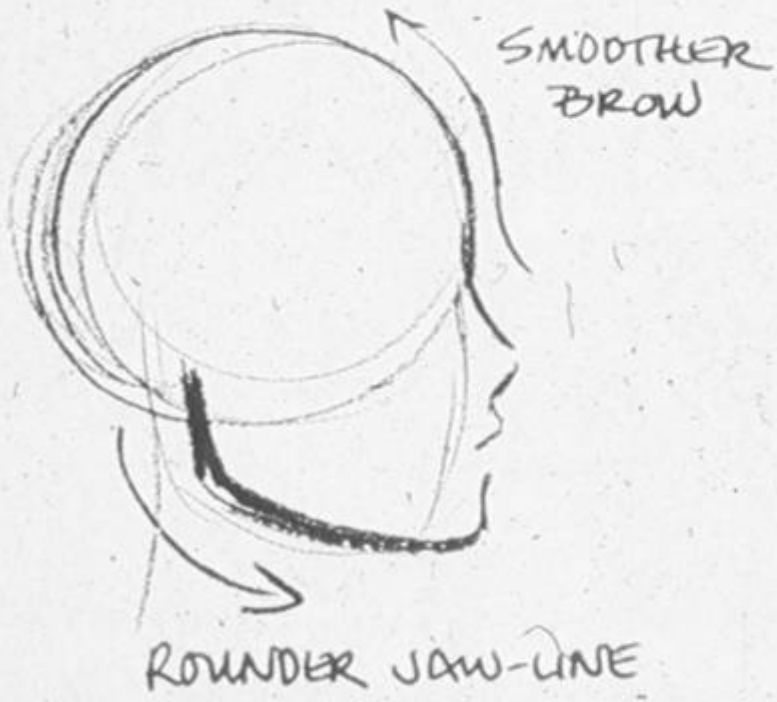

MALE

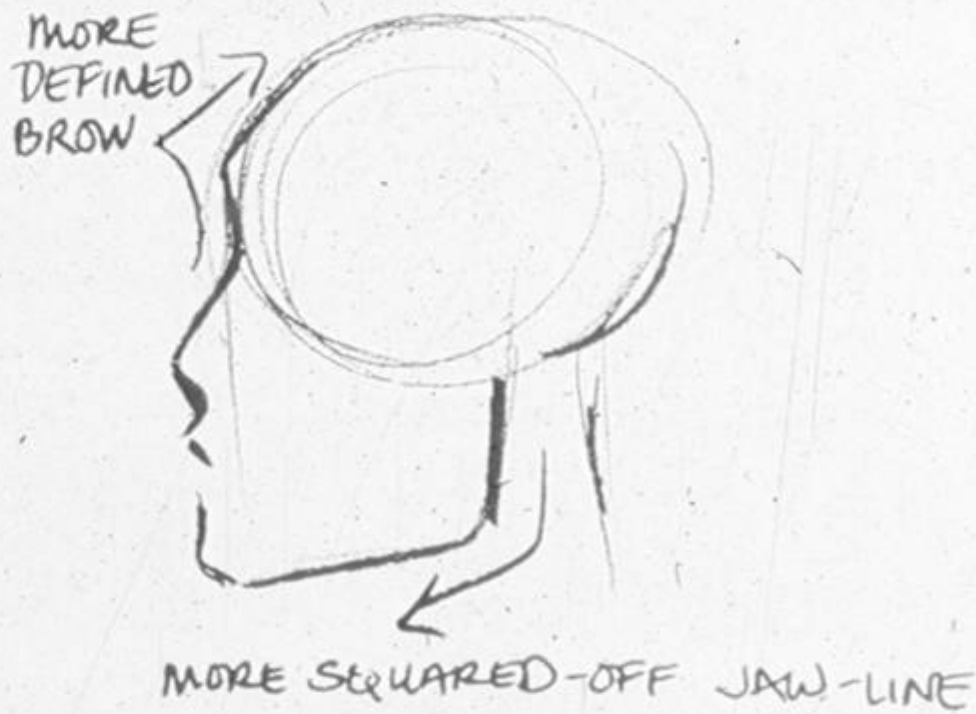

→ WOMEN MATURE EARLIER (TO HAVE BABIES)

SINCE → MORE BONE DEPOSITS, THE LATER ONE MATURES, IT IS LOGICAL THAT MALES WOULD HAVE "HEAVIER" BROW + JAW BONE.

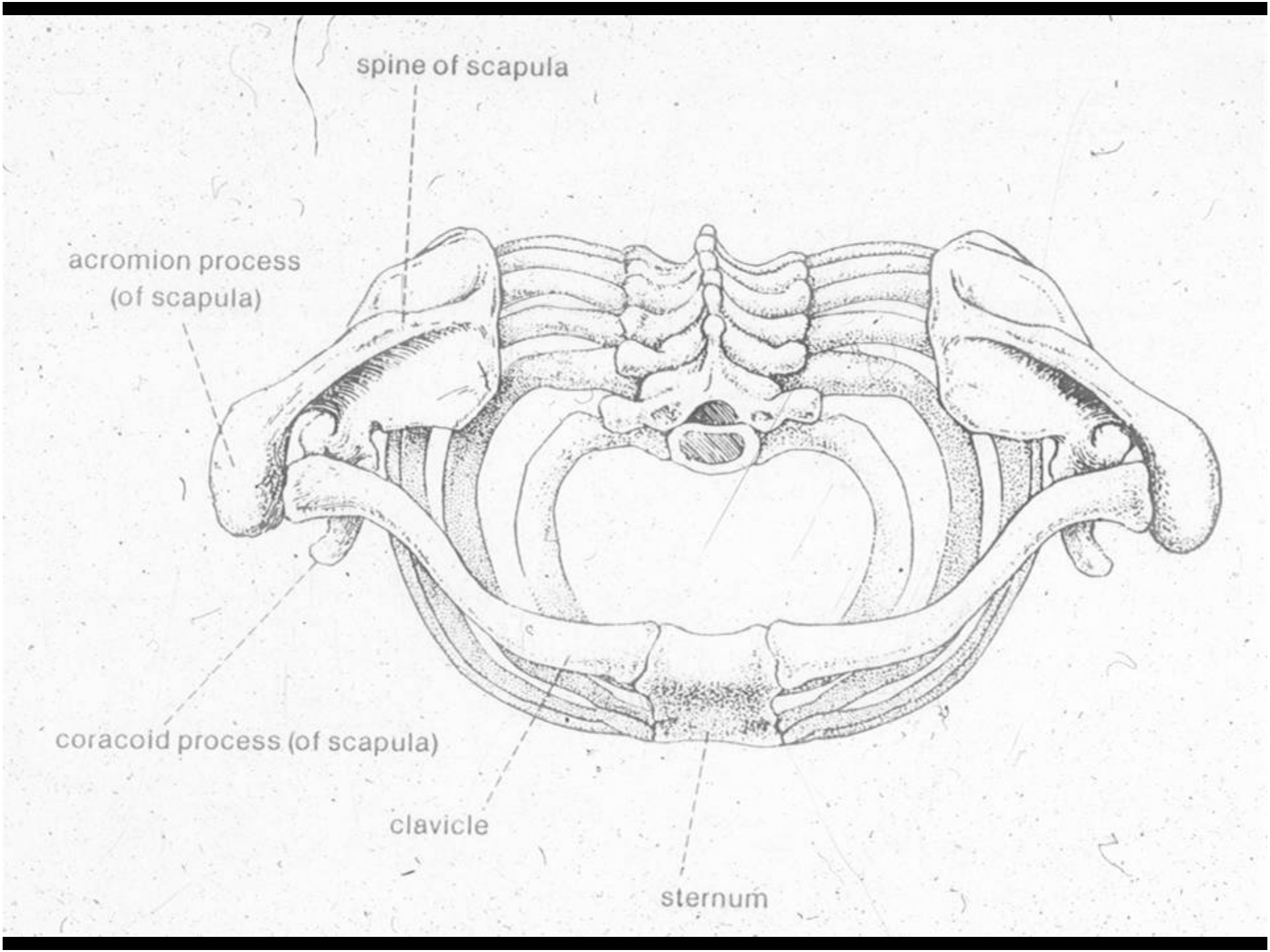
spine of scapula
acromion process
(of scapula)
coracoid process (of scapula)
clavicle
sternum

Locomotion:

Walking

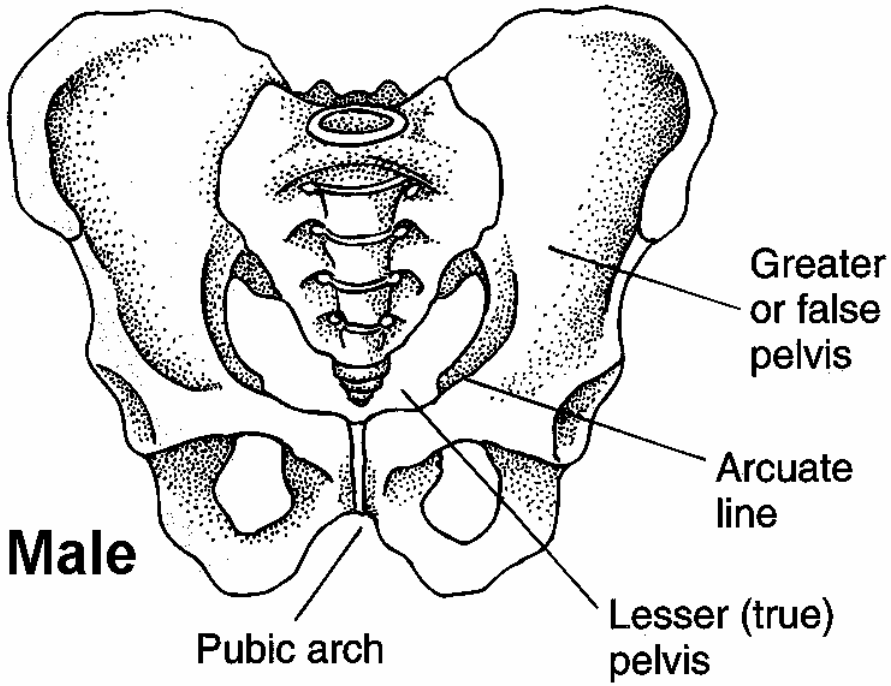
Greater
or false
pelvis
Arcuate
line
Male
Lesser (true)
pelvis
Pubic arch

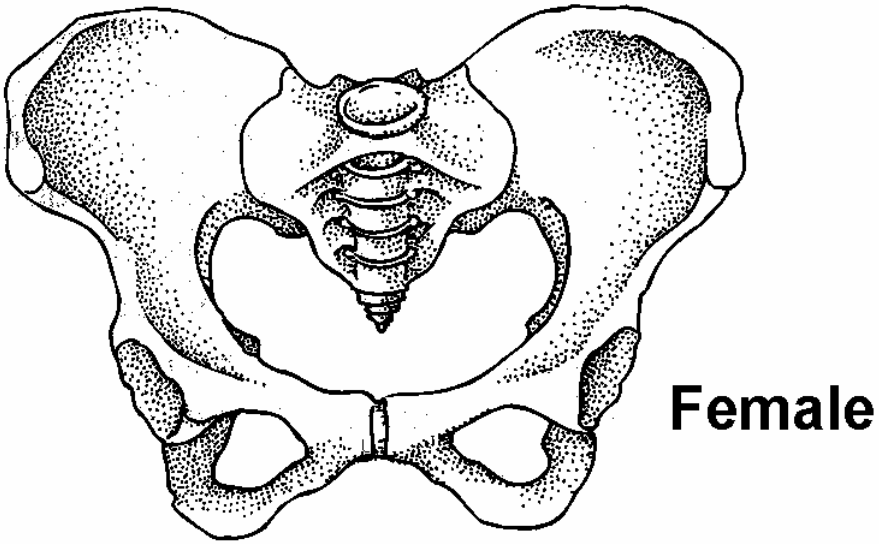
Female

Walking: Has a Double Support Phase

Support Phase = when foot is on the ground.

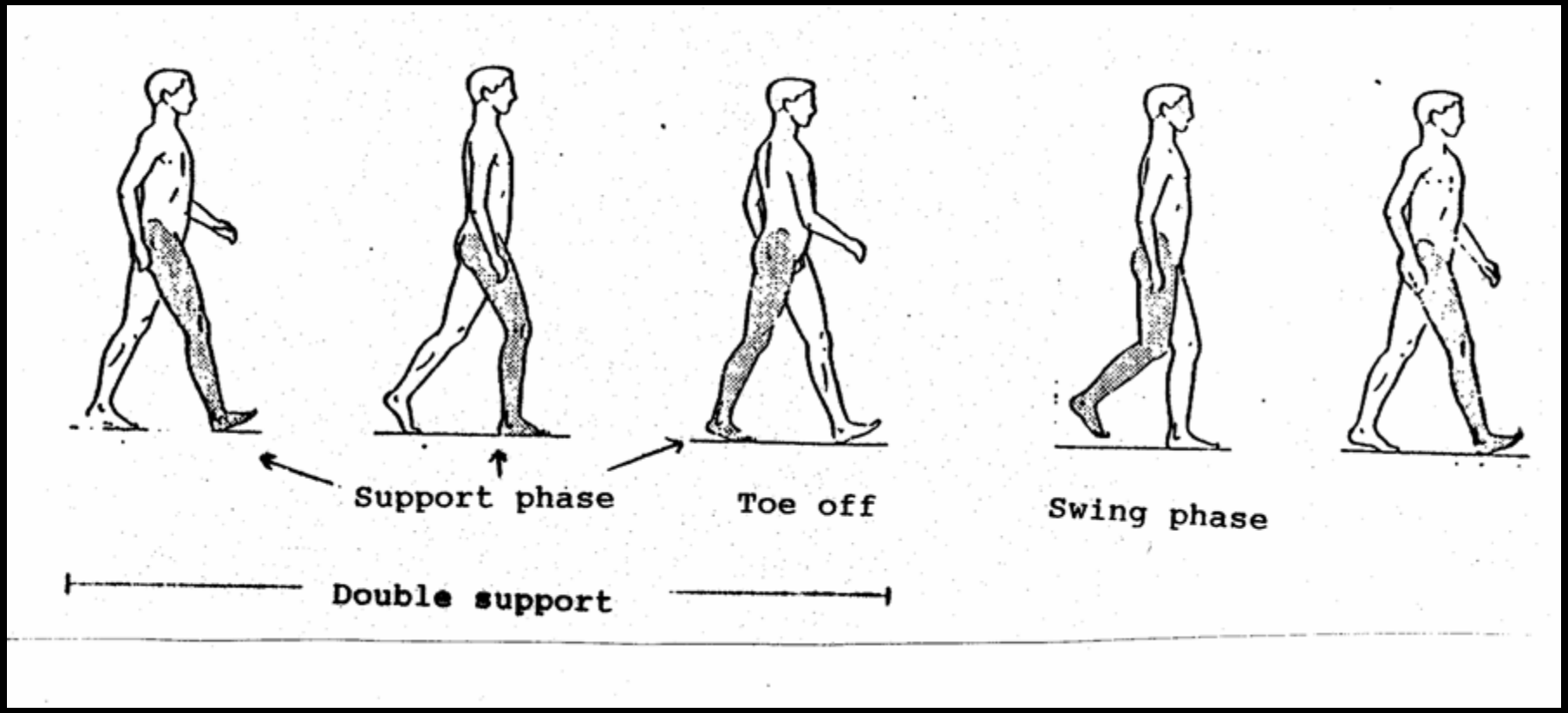

The leg is like an inverted pendulum when walking...

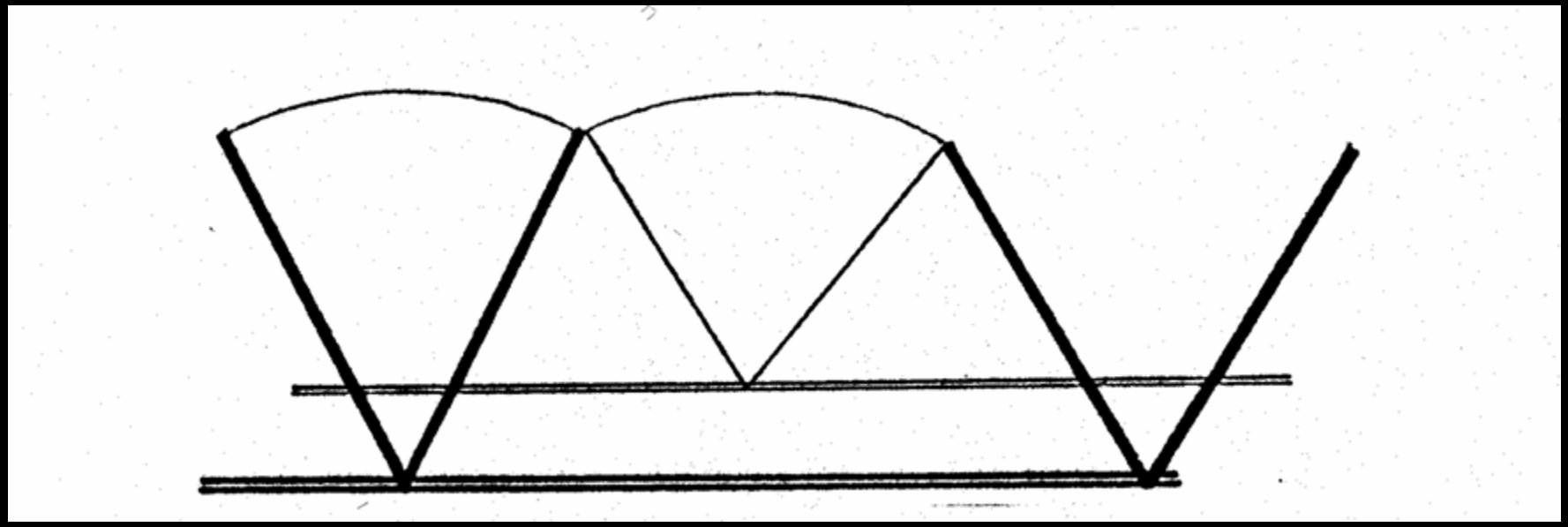

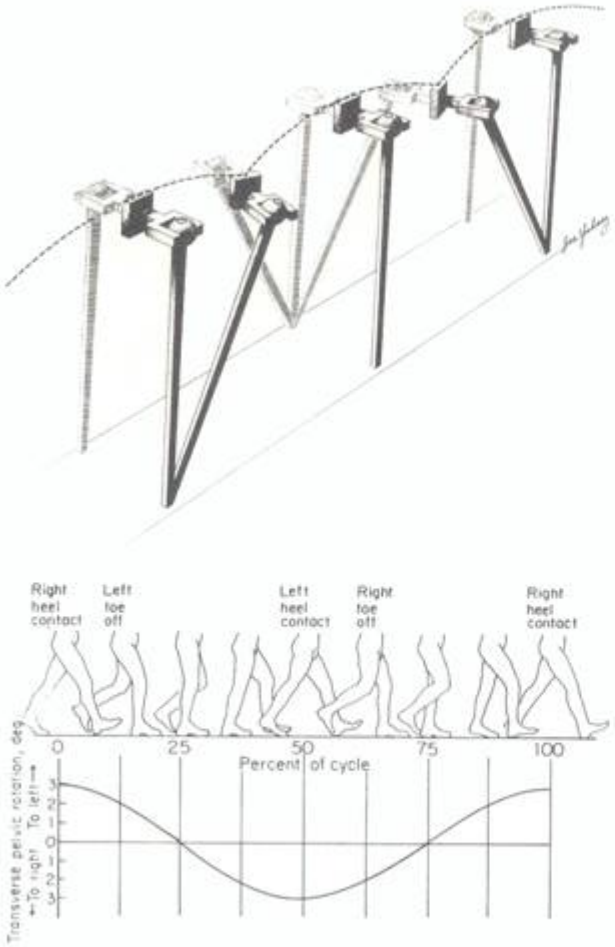

In pelvic rotation, the pelvis turns about a vertical axis, lengthening the step and flattening the arcs by increasing the effective length of the leg. From Inman, Ralston, and Todd (1981). Originally published in slightly different form in Saunders et al. (1953).

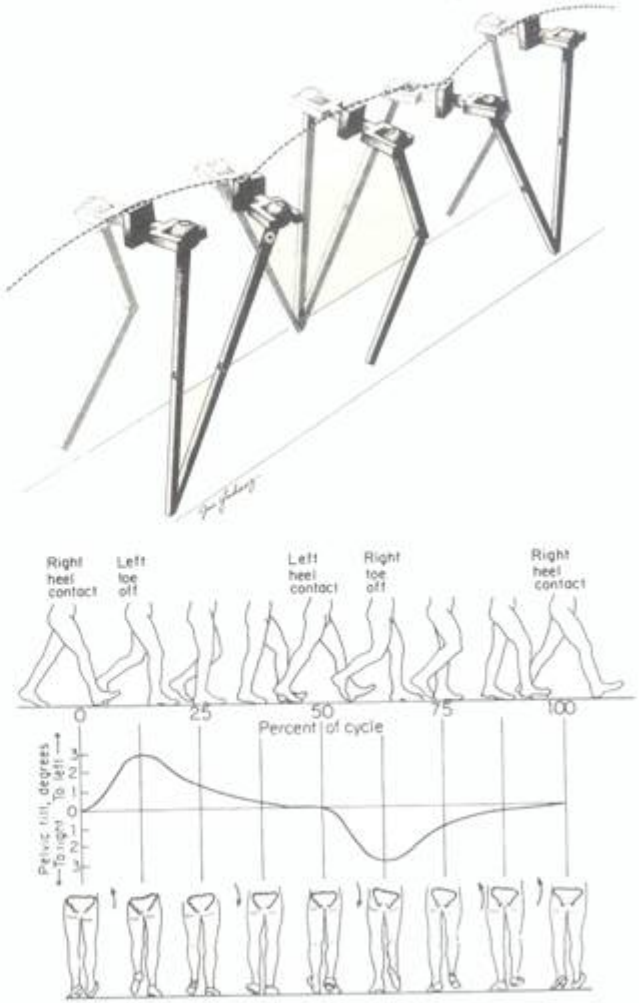

Adding pelvic tilt to pelvic rotation flattens the arcs further. Just before toe-off, the pelvis is lowered abruptly on the swing leg side, then raised slowly until heel strike. From Inman, Ralston, and Todd (1981). Originally published in slightly different form in Saunders et al. (1953).

Nine Factors Influencing Walking:

1. Pelvic Rotation
2. Pelvic Tilt
3. Lateral Displacement of Pelvis
4. Bending of the Knee
5. Lateral Flexion of Trunk
6. Antero-posterior Flexion of Trunk
7. Dorsiflexion of Foot
8. Plantarflexion of Foot
9. Compliance of Foot

1. Pelvic Rotation

Lateral-medial axis
of pelvis rotates about
the center when walking.

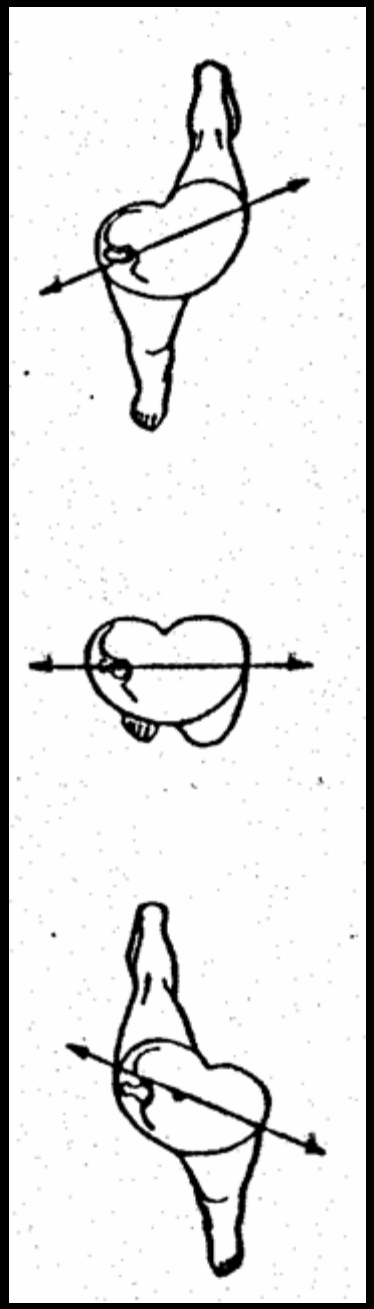

2. Pelvic Tilt

Hip tilts to compensate for the weight of the swing leg.

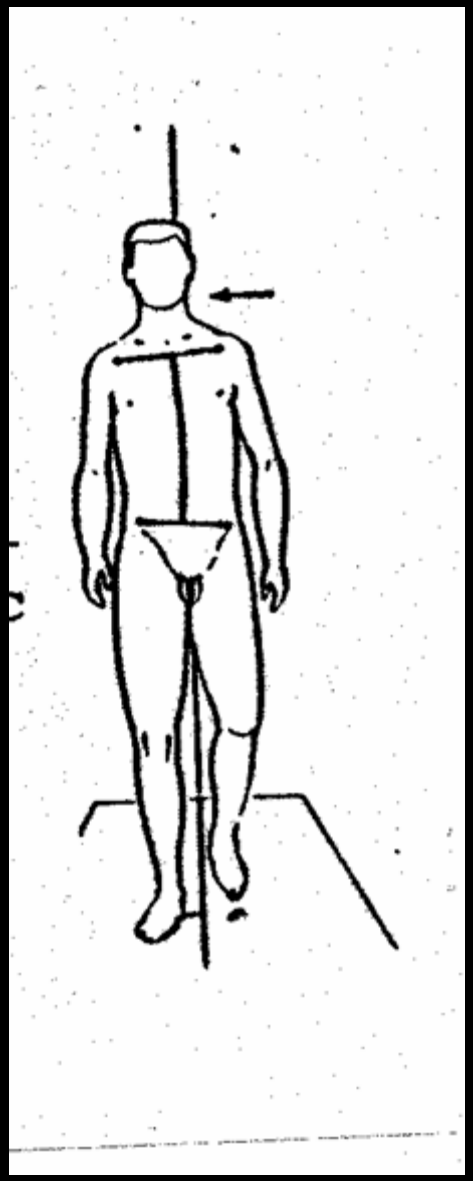

3. Lateral Displacement of Pelvis

Hips move from side to side to keep center of mass over support limb.

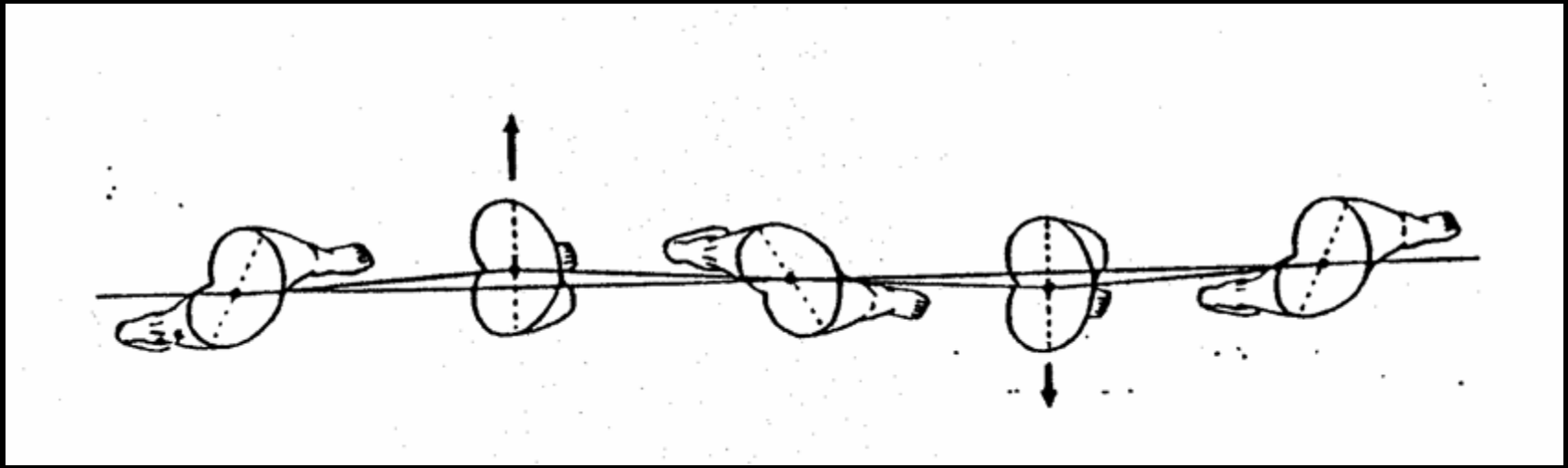

4. Bending of the Knee

Knee bends between heel-strike and pushoff.

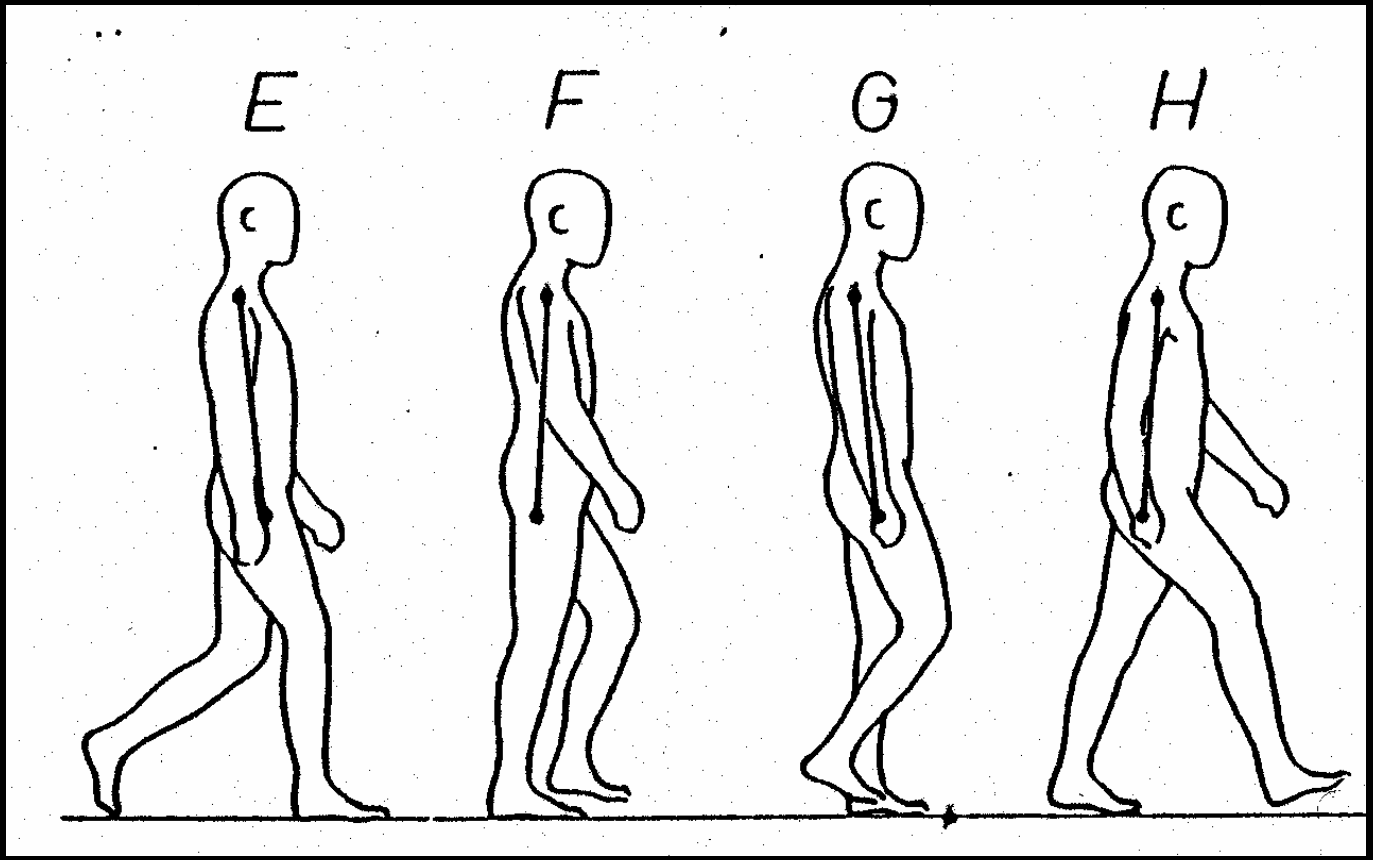

5. Lateral Flexion of Trunk

Trunk flexes laterally to help to keep center
of mass over support limb.

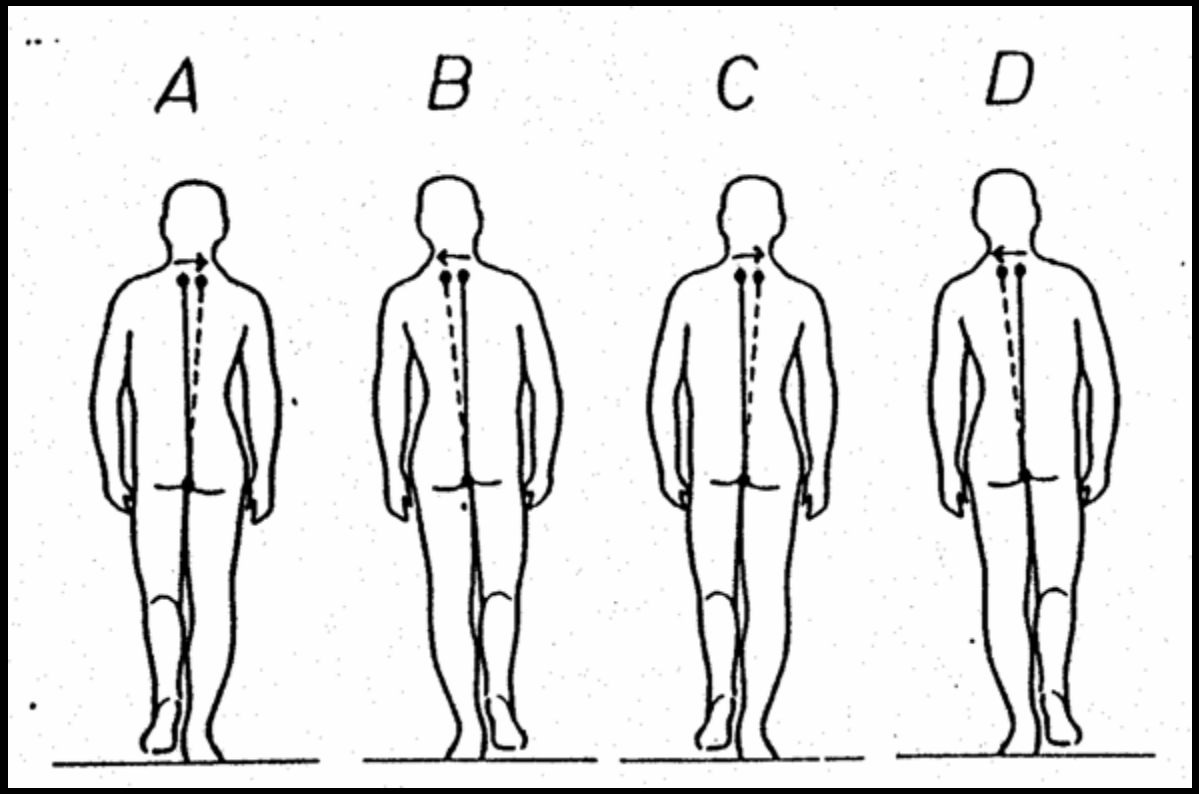

6. Antero-posterior Flexion of Trunk

Trunk flexes anteriorly and posteriorly to help keep center of mass over support limb.

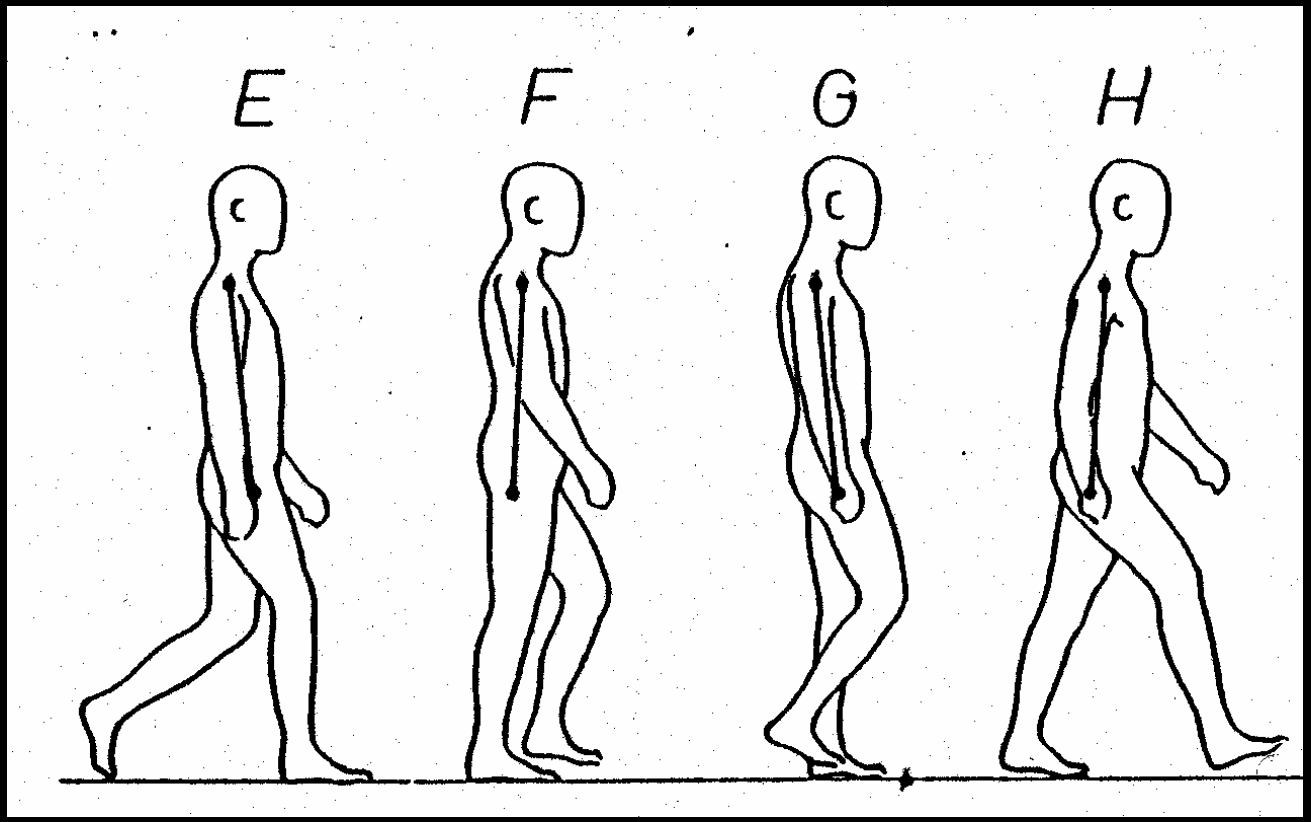

7. Dorsiflexion of Foot

•Foot flexes dorsally upon heel strike (with
locked knee).
•Catches falling body.

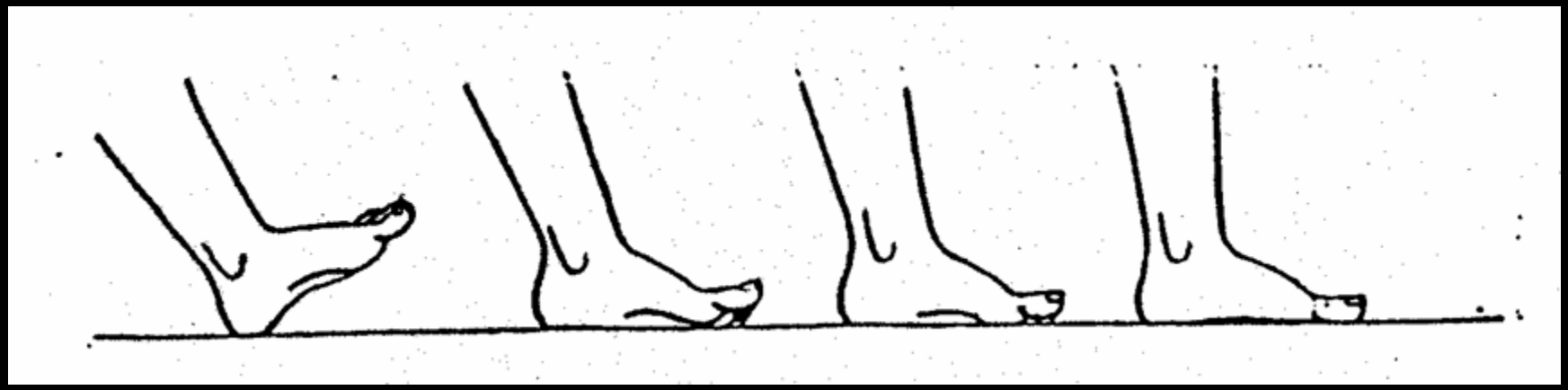

8. Plantarflexion of Foot

Plantarflexion of foot provides power for toeoff.

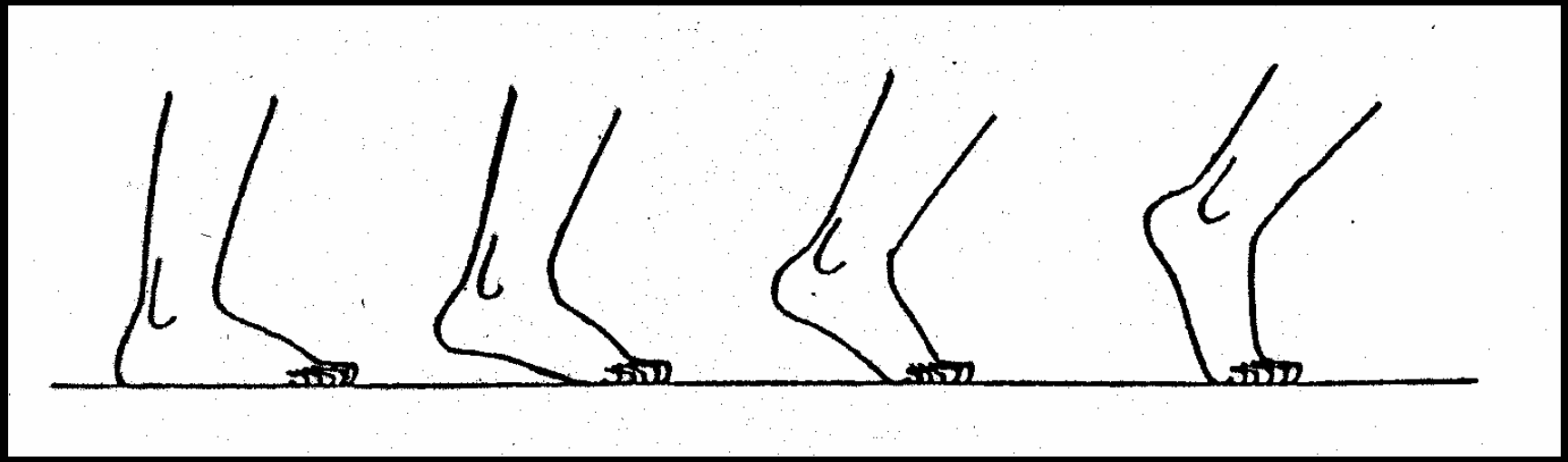

9. Compliance of Foot

Flexibility of foot smooths oscillation at other joints.

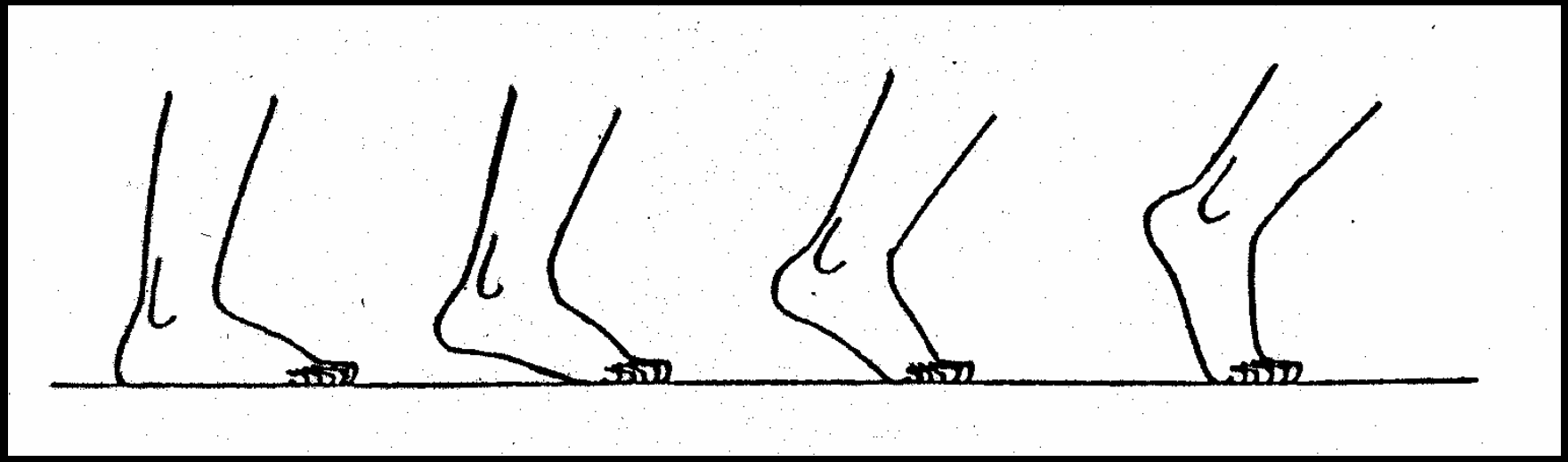

Fig. 61. Baby and adult chimpanzee from Naef, 1926b. Naef remarks: "Of all animal pictures known to me, this is the most manlike" (p. 448).



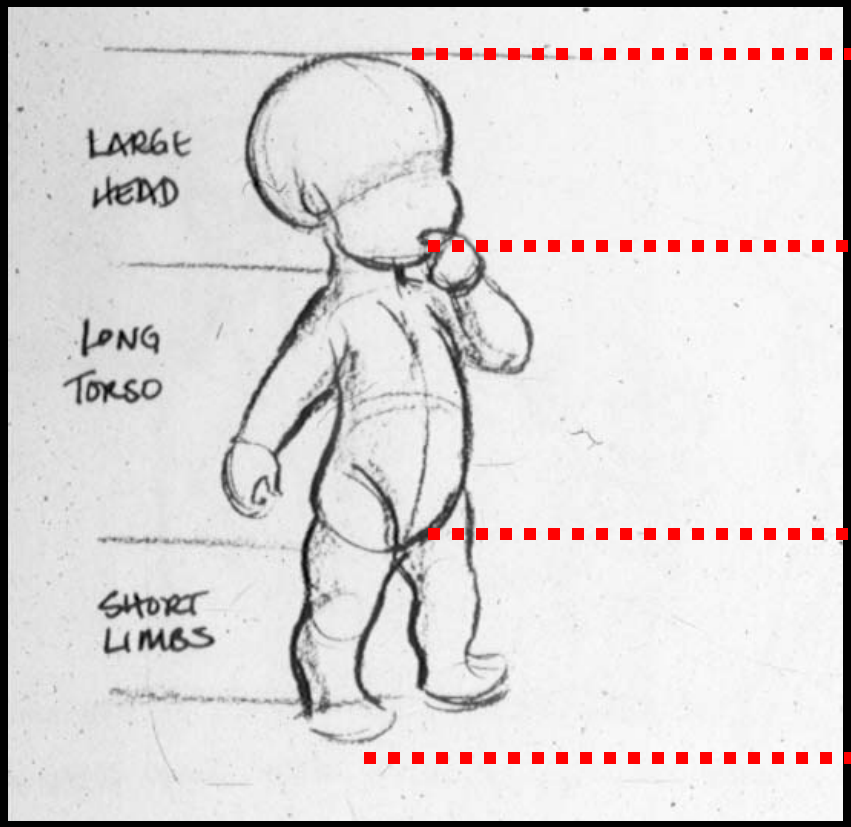
LARGE
HEAD
LONG
TORSO
SHORT
LIMBS

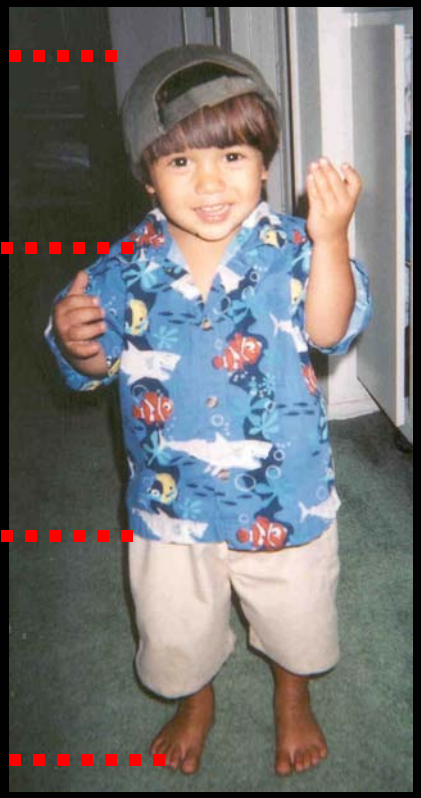


© Walt Disney Productions
Stage 1
Stage 2
Stage 3

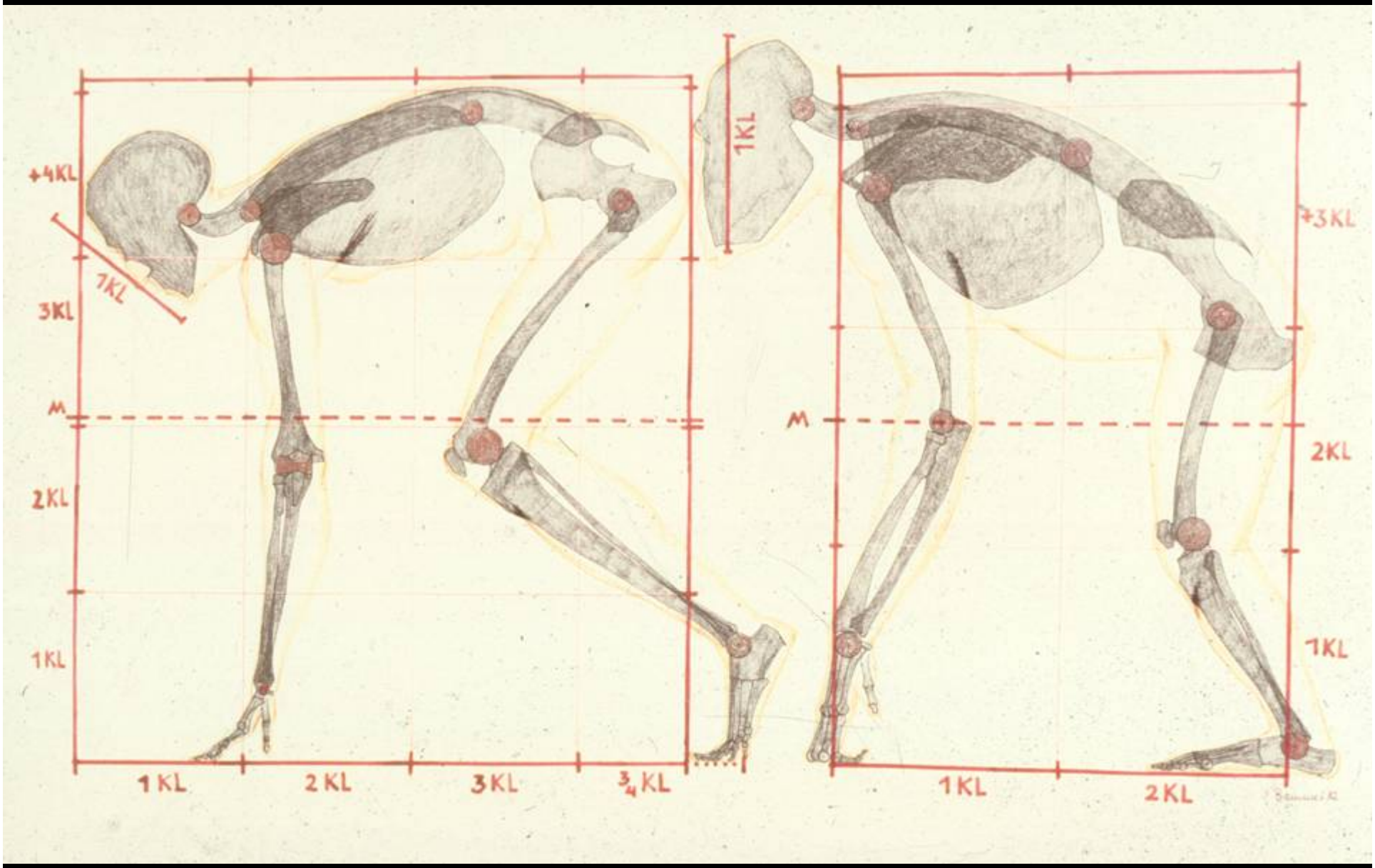
+4KL
1KL
3KL
M
2KL
1KL
1 KL
2 KL
3KL
3/4 KL
1KL
+3KL
M
2KL
1KL
1KL
2KL

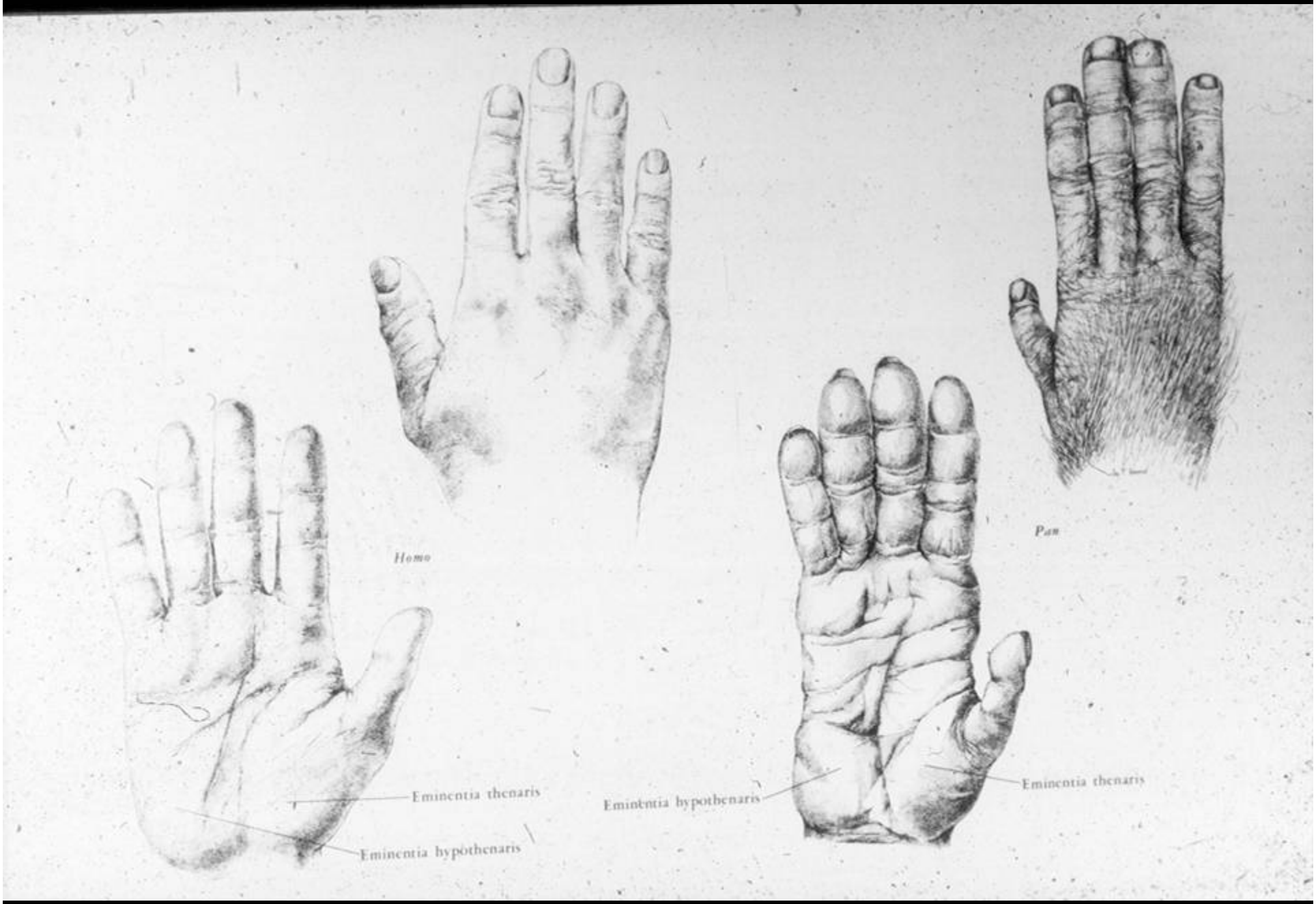
Homo
Eminentia thenaris
Eminentia hypothenaris
Pan
Eminentia hypothenaris
Eminentia thenaris



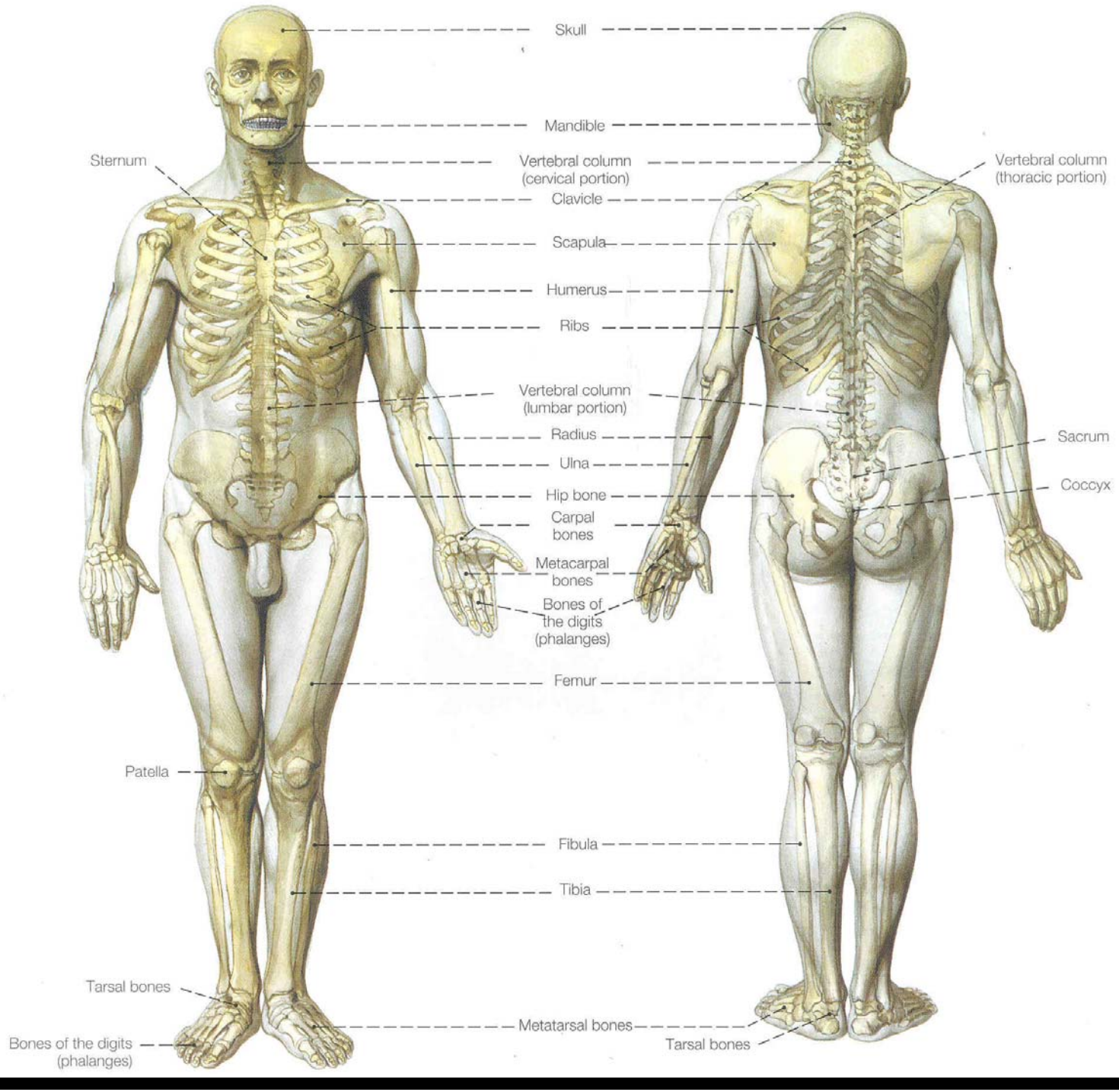
Skull
Mandible
Sternum
Vertebral column (cervical portion)
Vertebral column (thoracic portion)
Clavicle
Scapula
Humerus
Ribs
Vertebral column (lumbar portion)
Radius
Ulna
Sacrum
Coccyx
Hip bone
Carpal bones
Metacarpal bones
Bones of the digits (phalanges)
Femur
Patella
Fibula
Tibia
Tarsal bones
Metatarsal bones
Bones of the digits (phalanges)
Tarsal bones


SEE A DIFFERENT GAME.
BRUISED SHOULDER
BRUISED RIBS
STRAINED LIGAMENTS
The new Sporting News is now a full-co
And you get a deeper, sharper perspe
sports every week – the teams, stats,
in-season and out, so you can see a di


Sue
Myers
7