Biology 340
Comparative Embryology
Lecture 10
Dr. Stuart Sumida

Further Development of the Mesoderm (and Endoderm)

Further Development:

- Digestive System – Foregut, Midgut, Hindgut
- Heart and Aortic Arches
- Excretory and Reproductive Systems

Further Development:

Digestive System – Foregut, Midgut, Hindgut

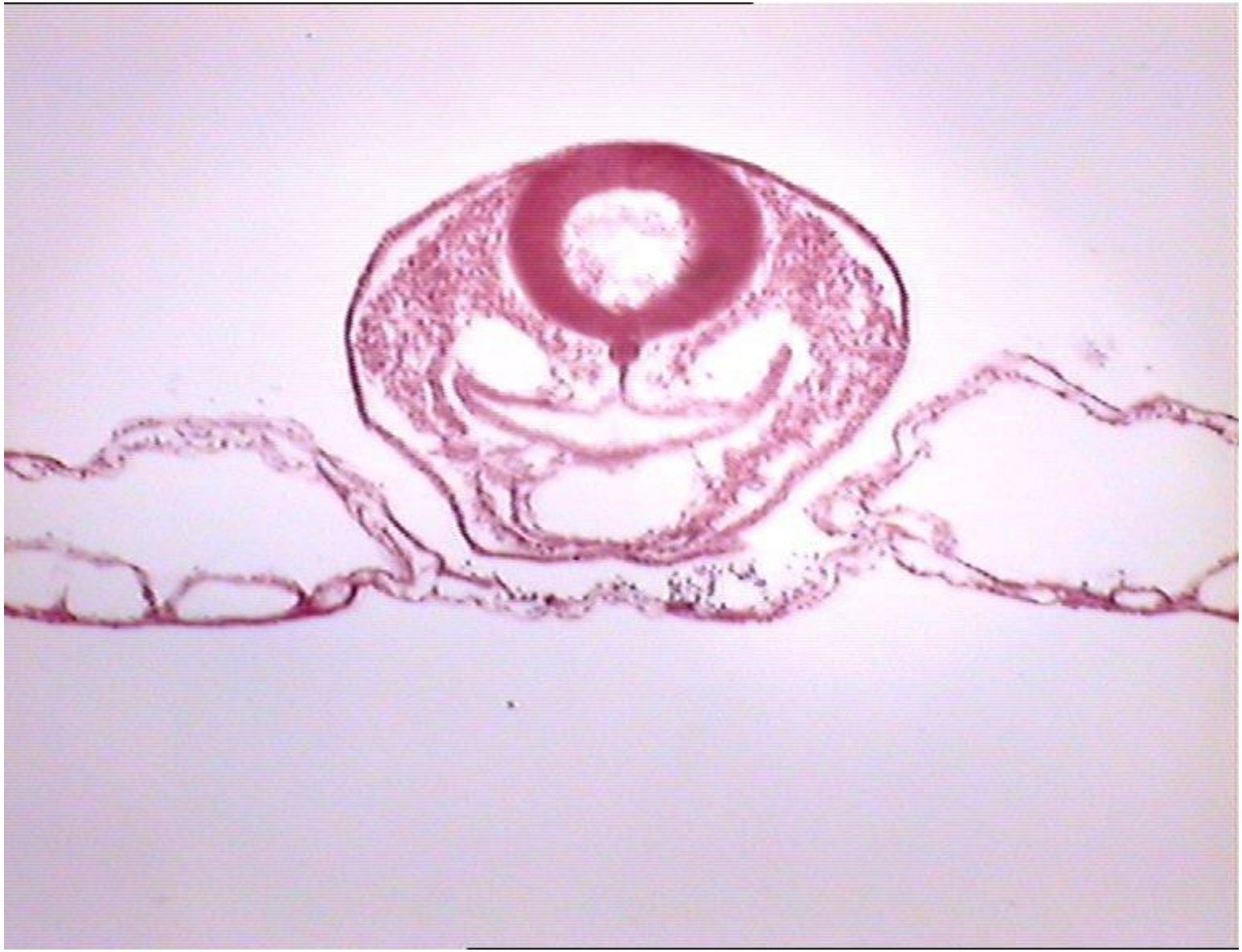

The brain grows at an incredible rate. It grows so fast that it makes the head bend around under the embryo's body. This completes the gut cranially (foregut) and caudally (hindgut) before the middle (midgut).

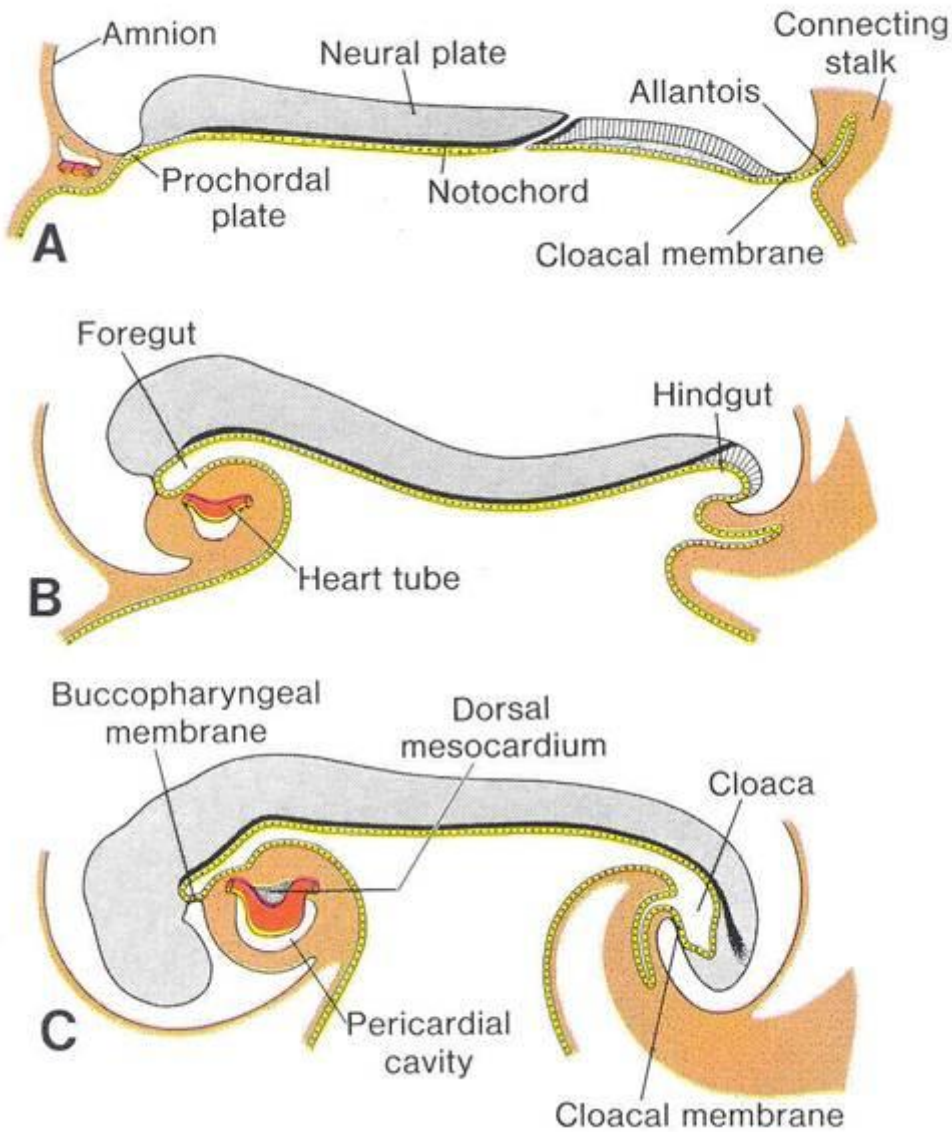

Do your own illustration here:

This creates a tri-partite division of the abdominal gut in vertebrates. The subdivision is so FUNDAMENTAL that nervous supply, arterial supply, and venous drainange all organize themselves around it(!!)

	Foregut	Midgut	Hindgut
Unpaired Abdominal Artery	Celiac Artery	Anterior Mesenteric Artery	Posterior Mesenteric Artery
Unpaired Hepatic Portal Vein	Splenic Vein	Anterior Mesenteric Vein	Posterior Mesenteric Vein
Sympathetic Nerve	Greater Splanchnic Nerve	Lesser Splanchnic Nerve	Least Splanchnic Nerve
Sympathetic Ganglion	Celiac Ganglion	**Anterior Mesenteric Ganglion**	**Posterior Mesenteric Ganglion**
Parasympathetic Nerve	Vagus (X)	Vagus (X)	Caudal Outflow

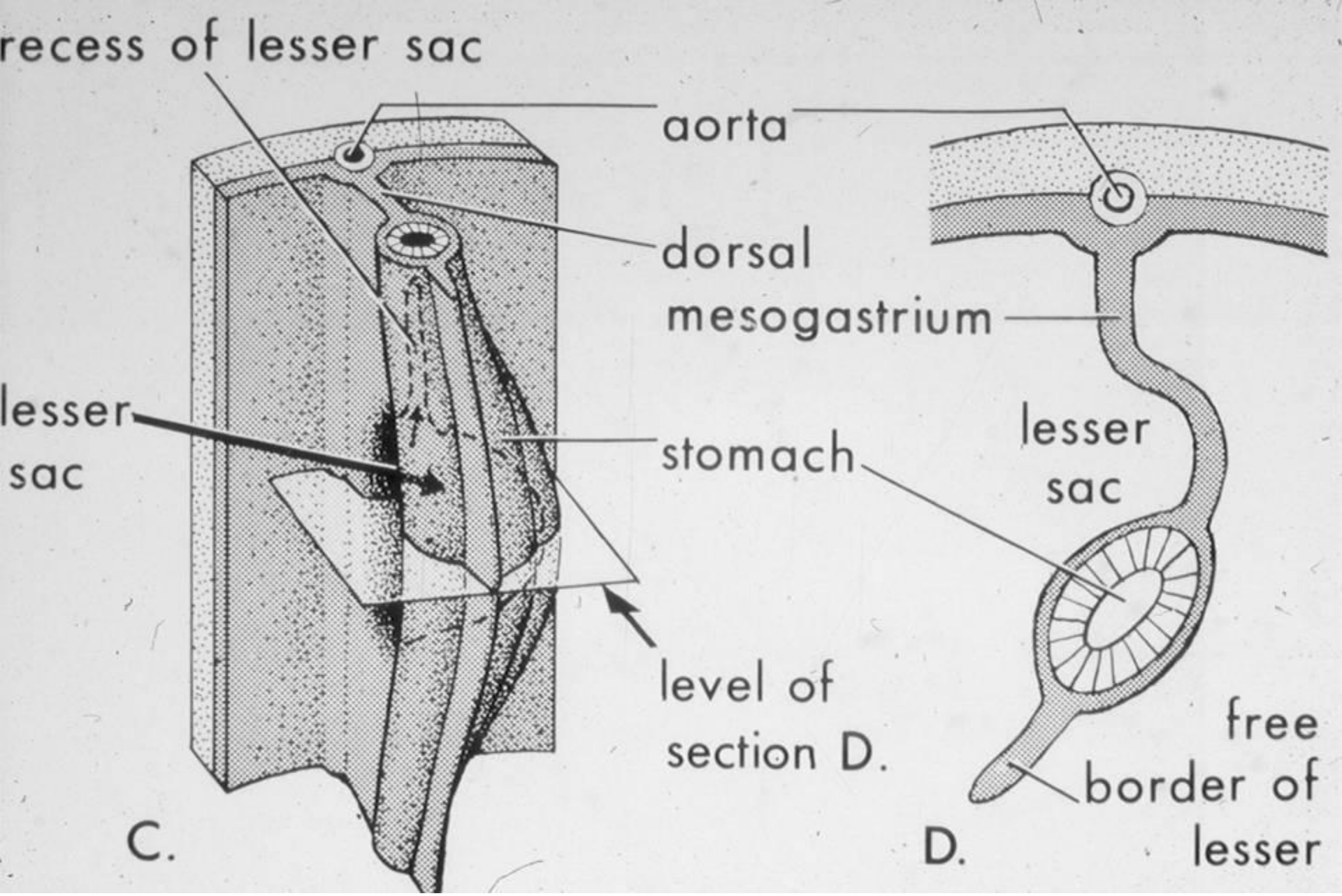

Further Development of the Foregut.

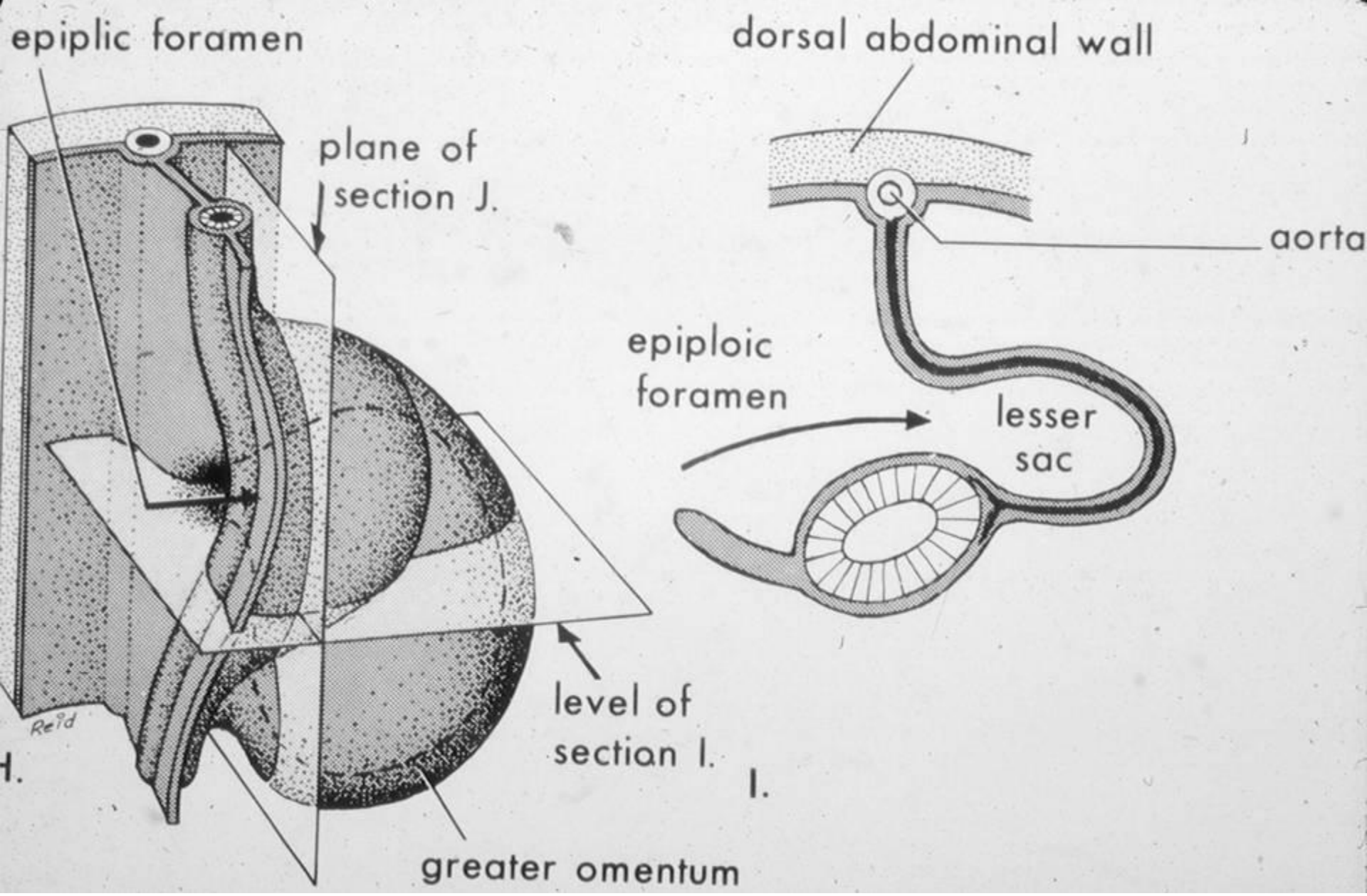

Further Development of the Foregut.

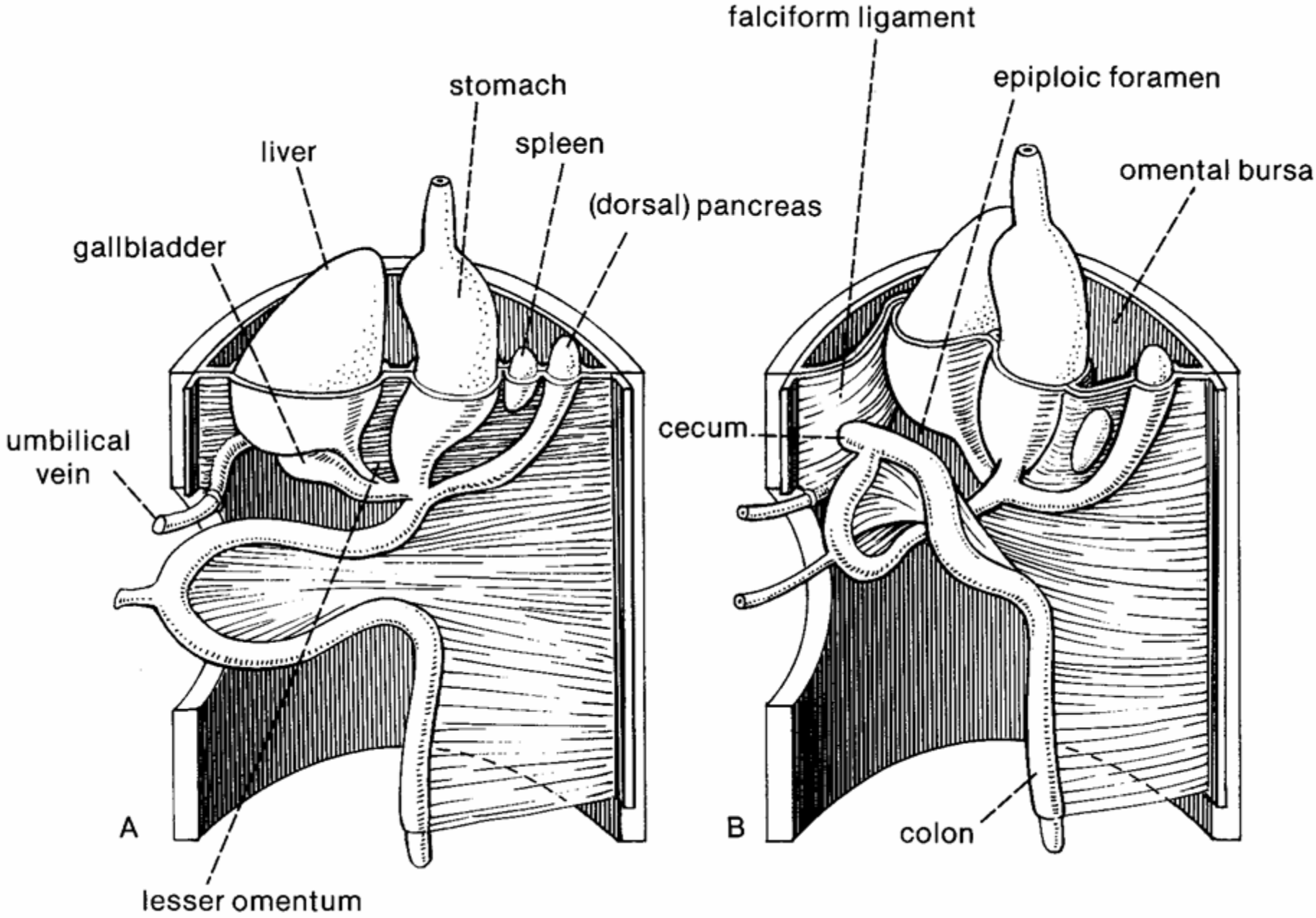

Further Development of the Foregut.

Do your own illustration here:

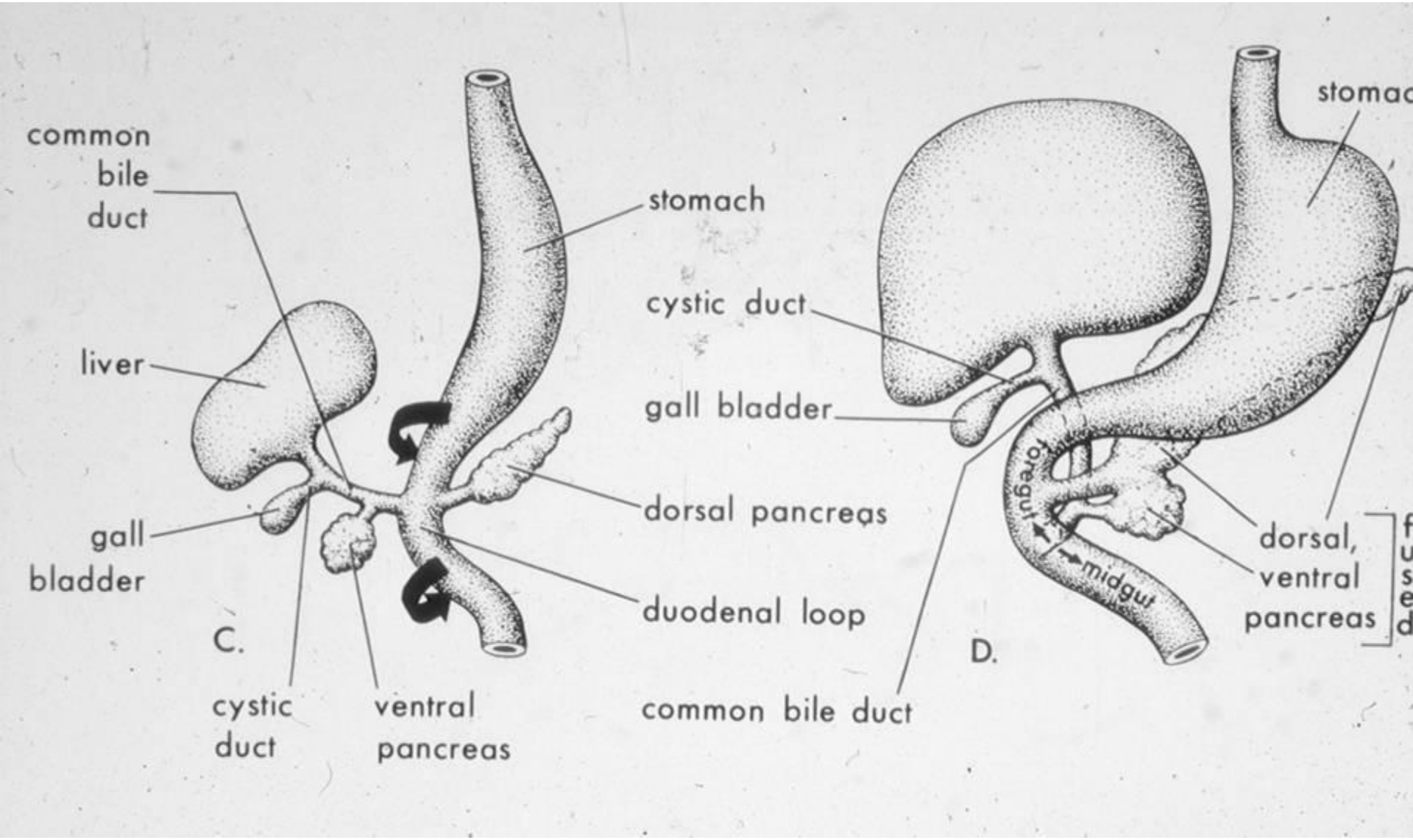

Development of diverticula of the foregut

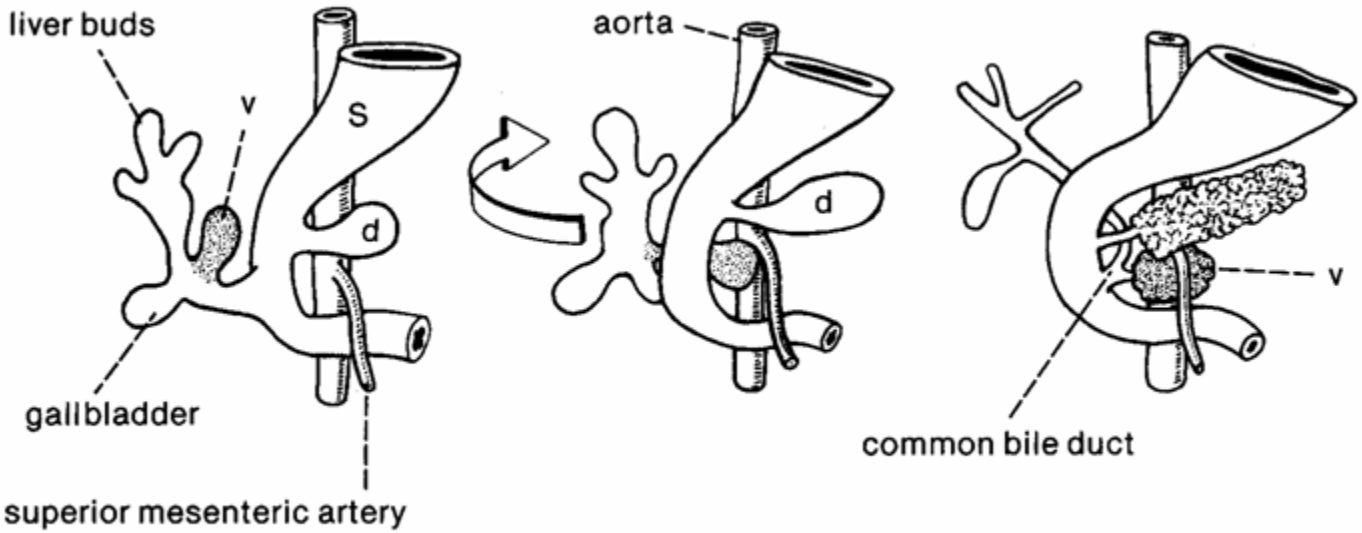

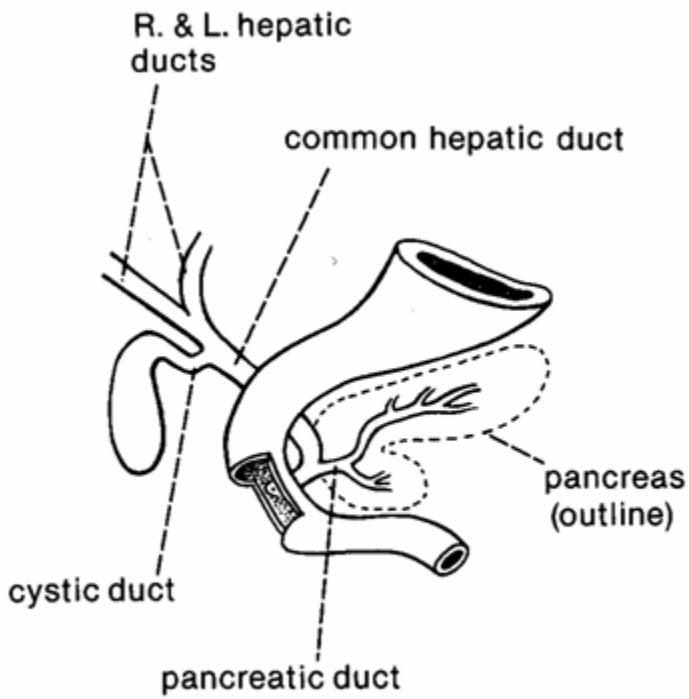

Pancreas Development

Further Development:

Heart and Aortic Arches

In amniotes: The first blood vessels of the embryo form inside the embryonic disc even before somites appear. They form near the edge of the yolksac (the primitive condition for macrolecithal amniotes that stored yolk for food).

Angiogenetic cell clusters extend in an arc around the head end of the ventral opening of the yolk sac. Initially, this means that the angiogenetic cell clusters (and the blood vessel that forms from them) have the pattern of a "horseshoe" if viewed from a dorsal or ventral perspective.

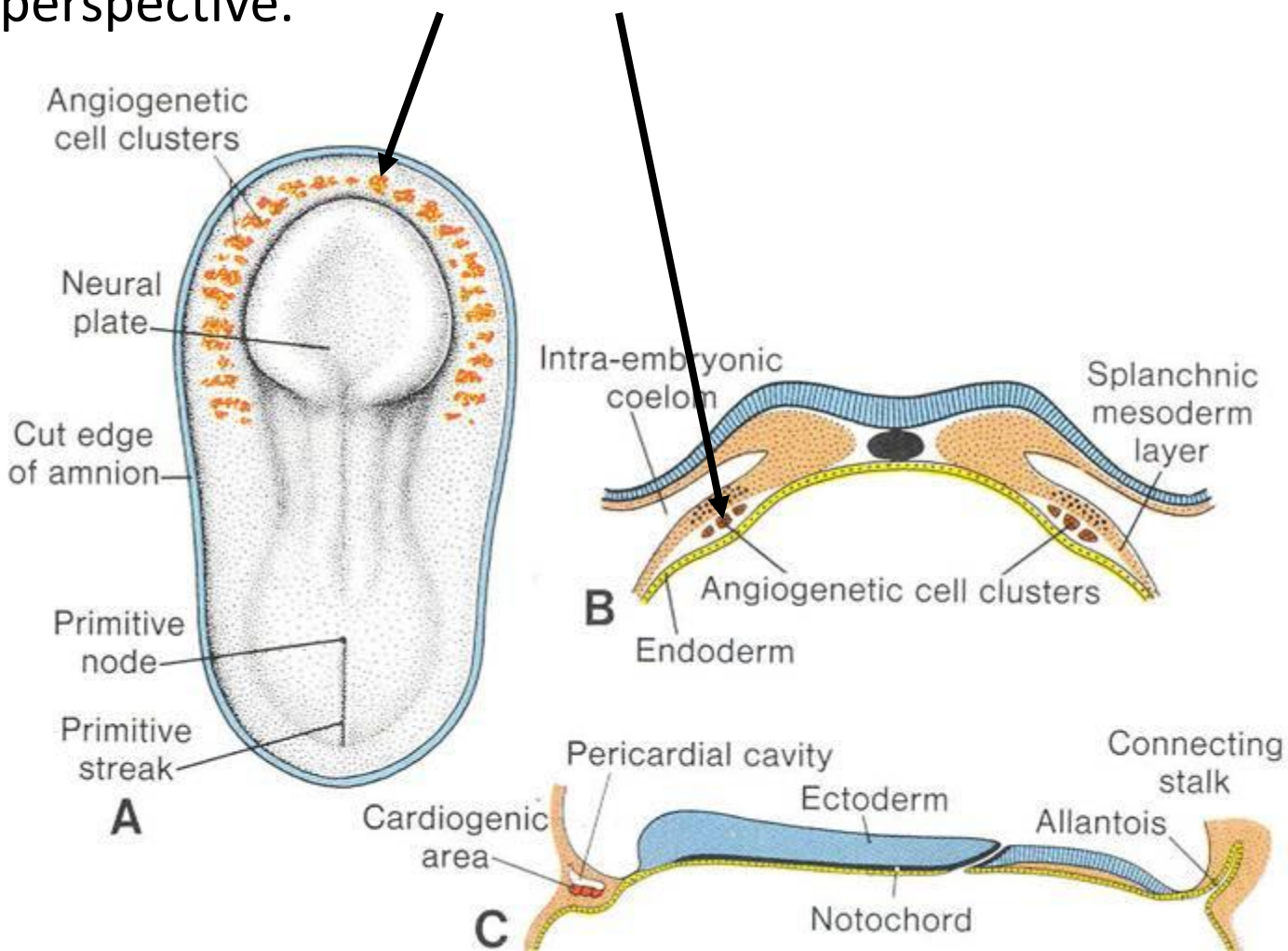

An important point to understand is that the coelom runs up and down either side of the body.

At the head end, right underneath the developing pharynx, the coelom on the left communicates with the coelom on the right.

Thus, the coelom cuts across the midline here.

The brain grows at an incredible rate. It grows so fast that it makes the head bend around under the embryo's body.

This is why the heart winds up on the VENTRAL SIDE of the body.

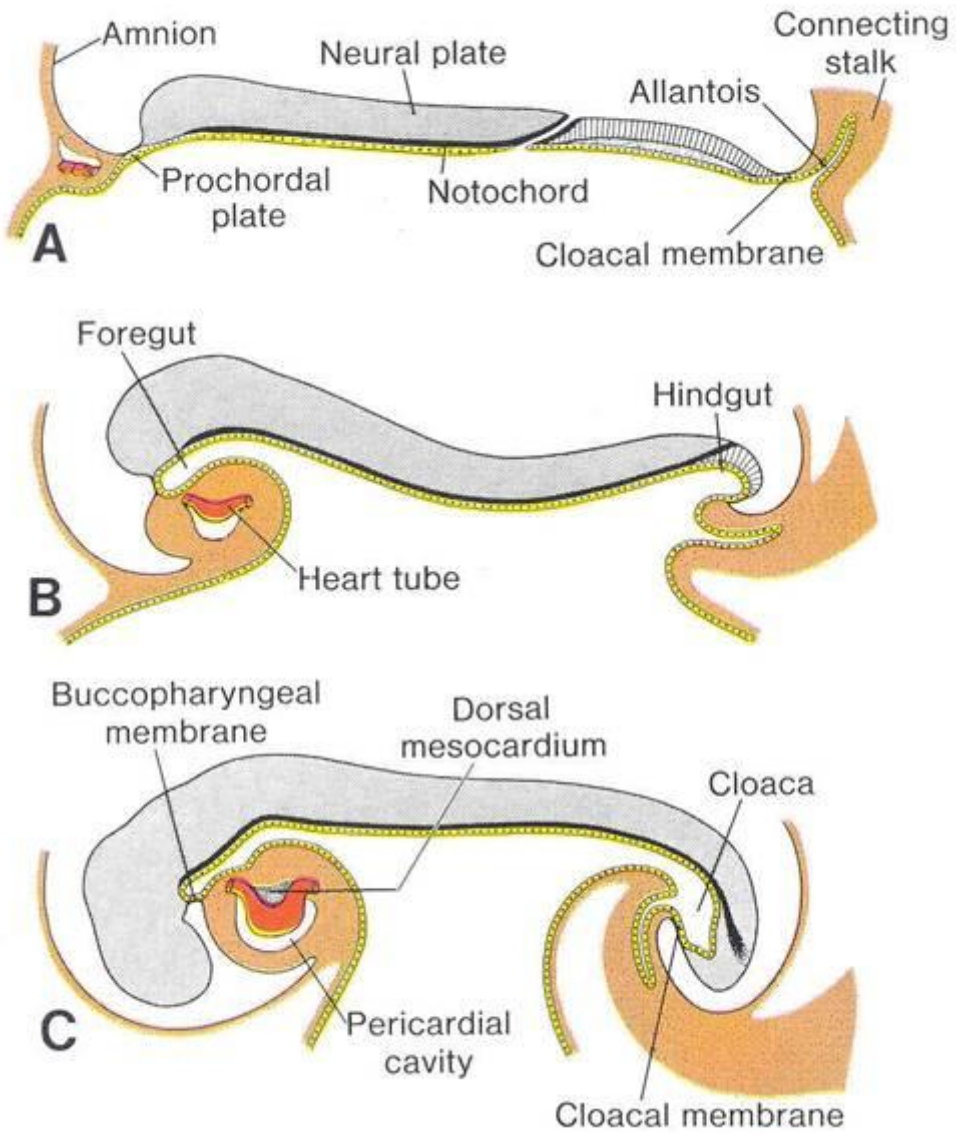

Amniote Heart Development

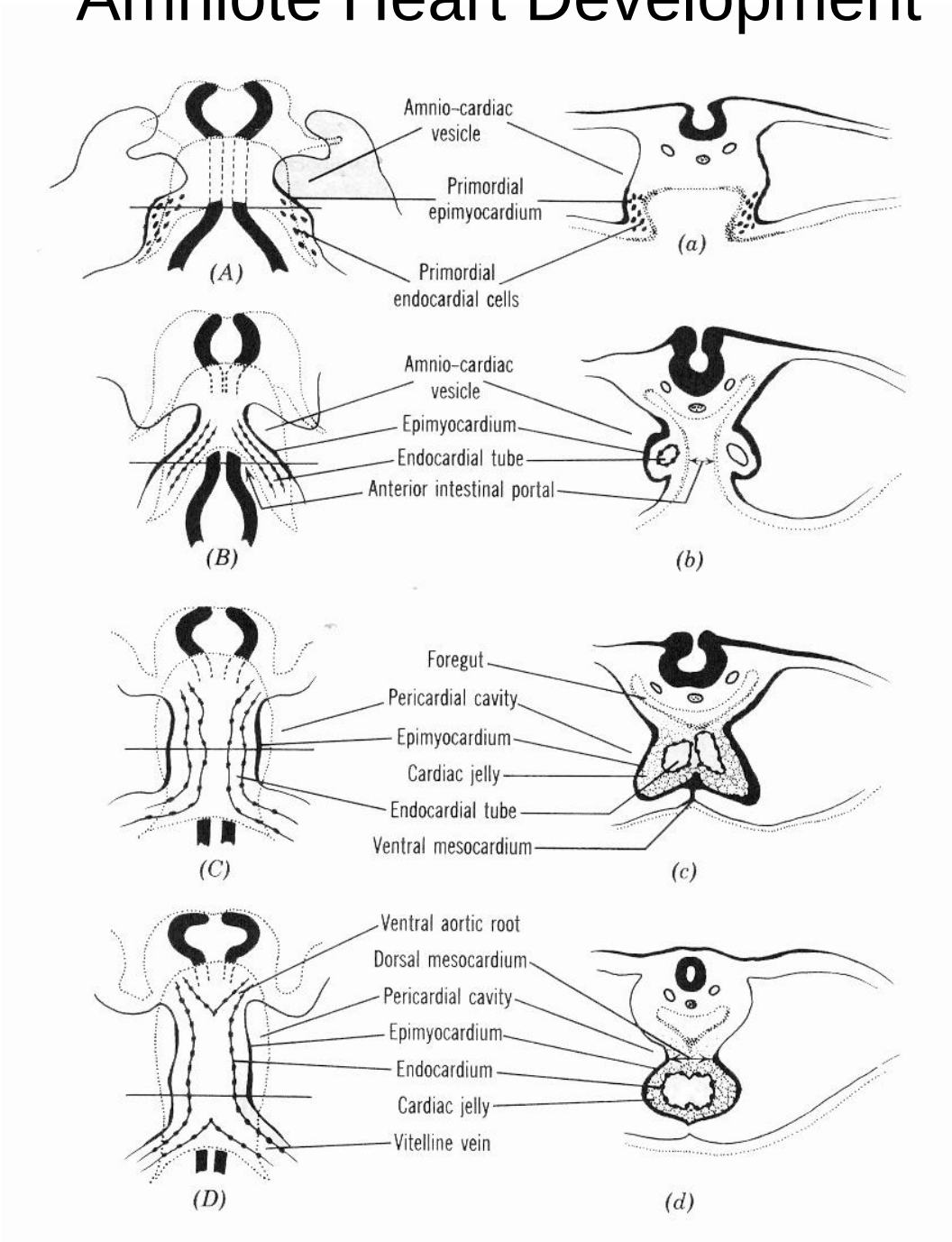

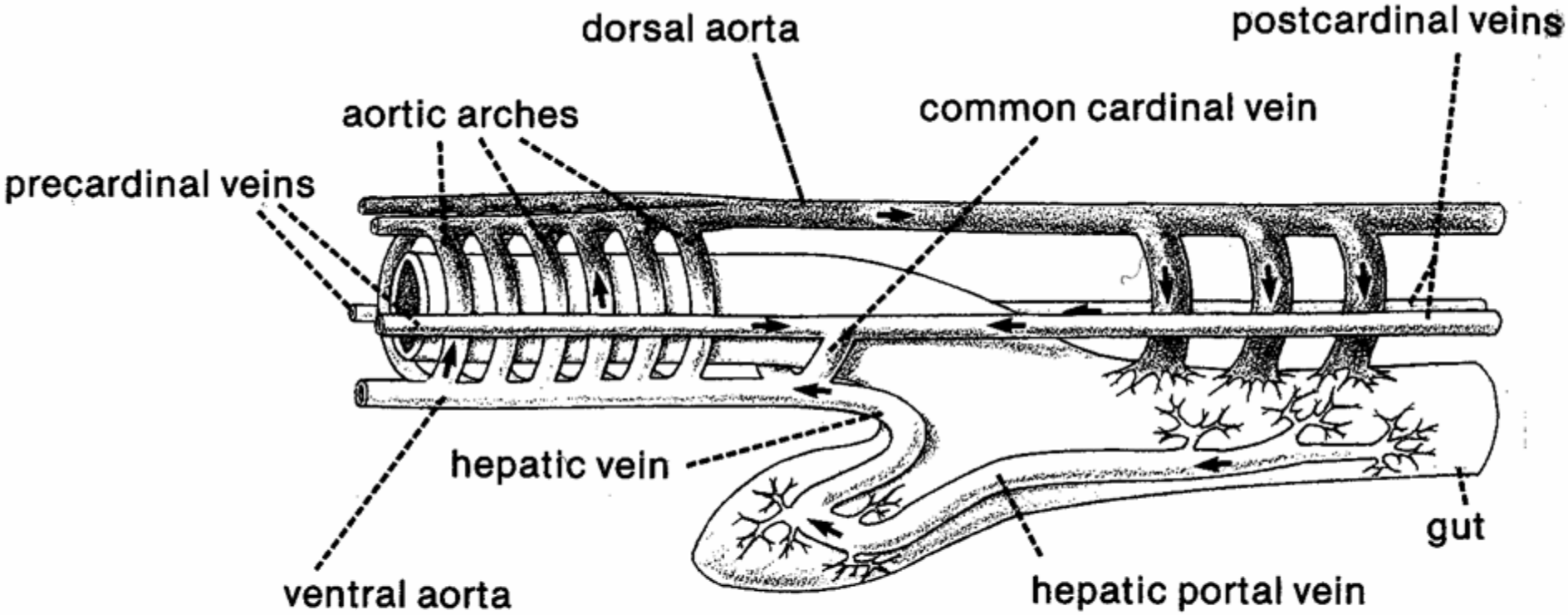
dorsal aorta
postcardinal veins
aortic arches
common cardinal vein
precardinal veins
hepatic vein
gut
ventral aorta
hepatic portal vein

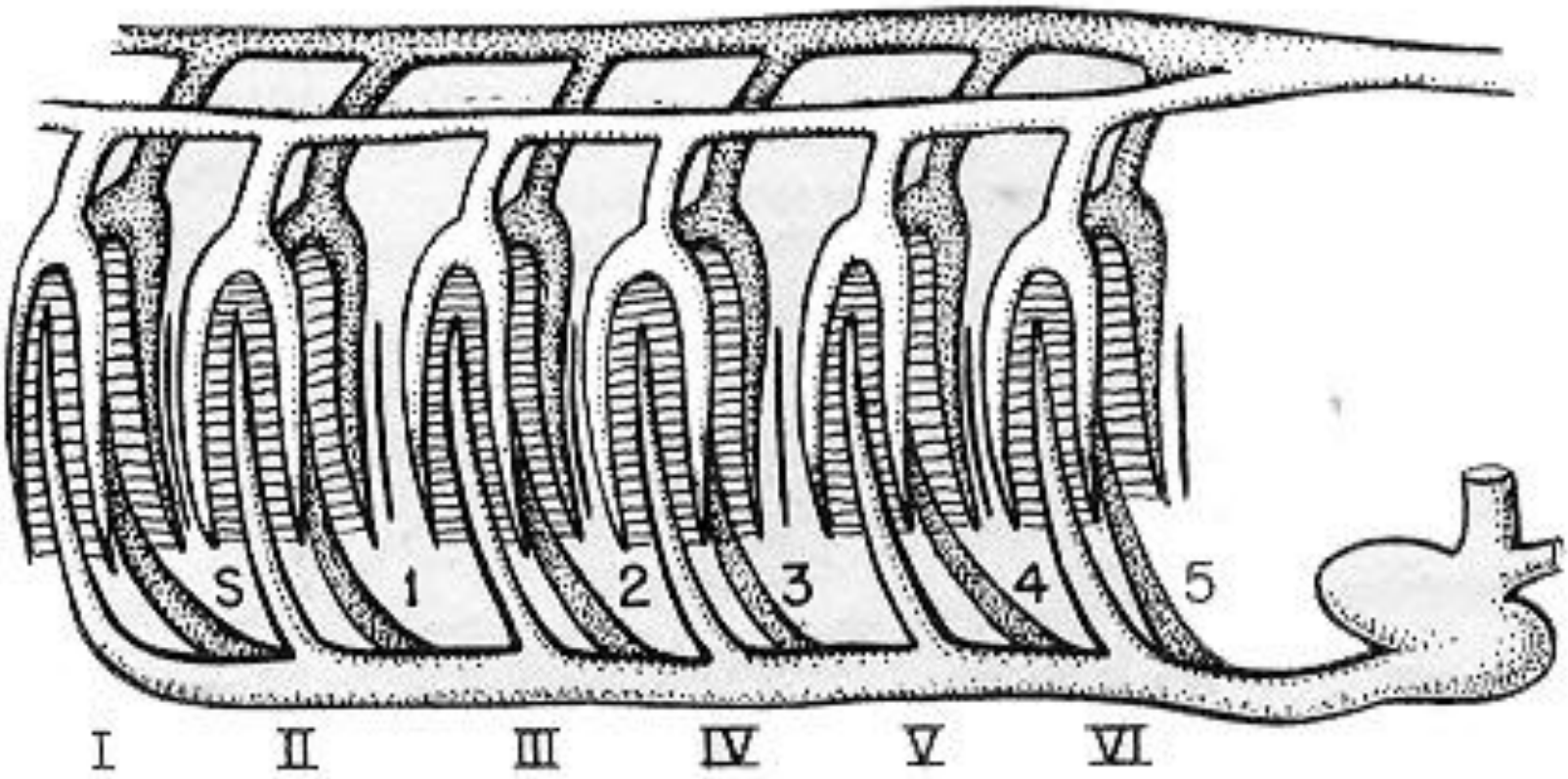

Aortic Arch Pattern of a Generalized Vertebrate Embryo

Draw Generalized View, Ventral Aspect here:

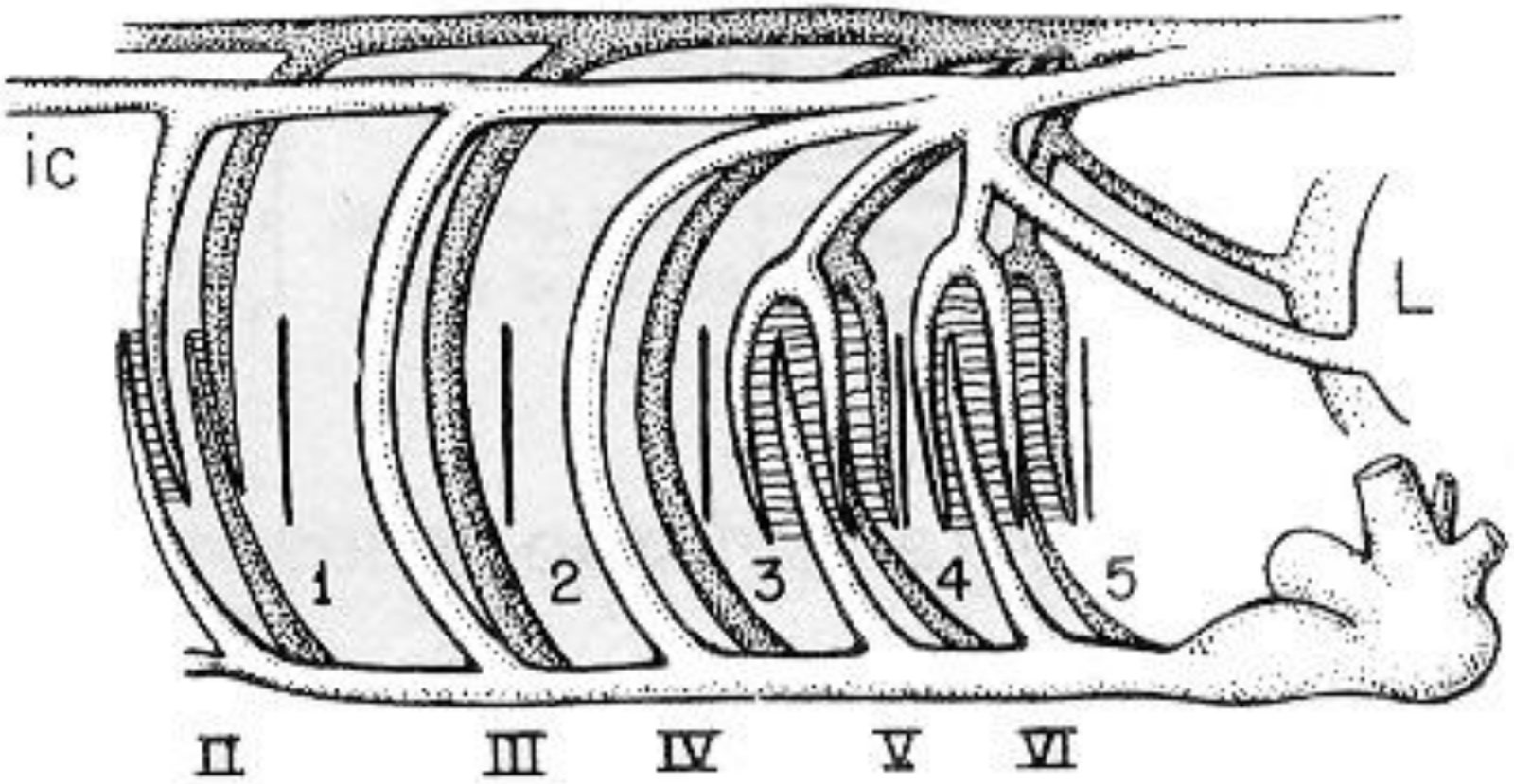

Aortic Arch Pattern of a Lungfish

Draw Lungfish, Ventral Aspect here:

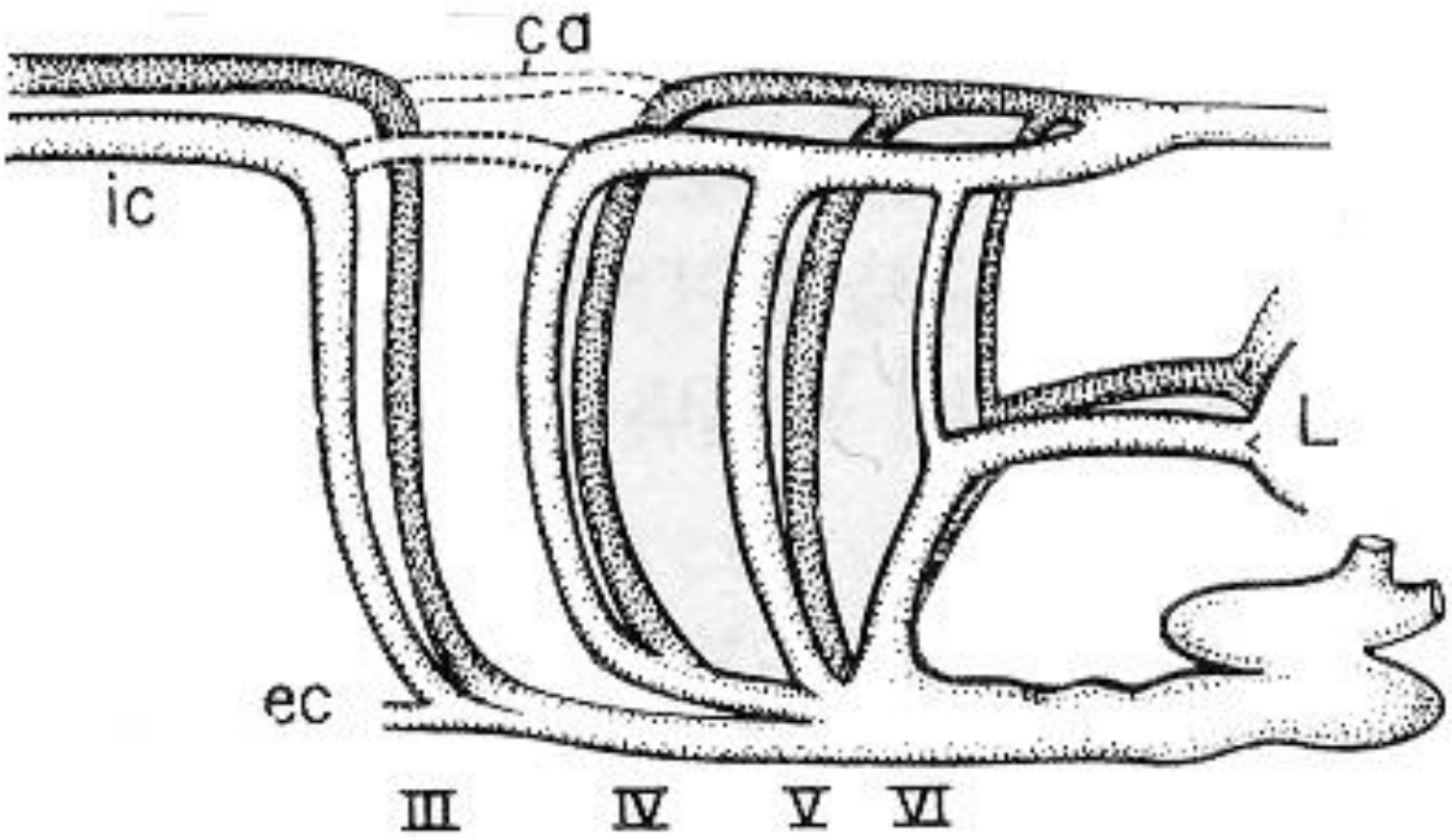

Aortic Arch Pattern of an Amphibian (Lateral Aspect) (in this case a salamander)

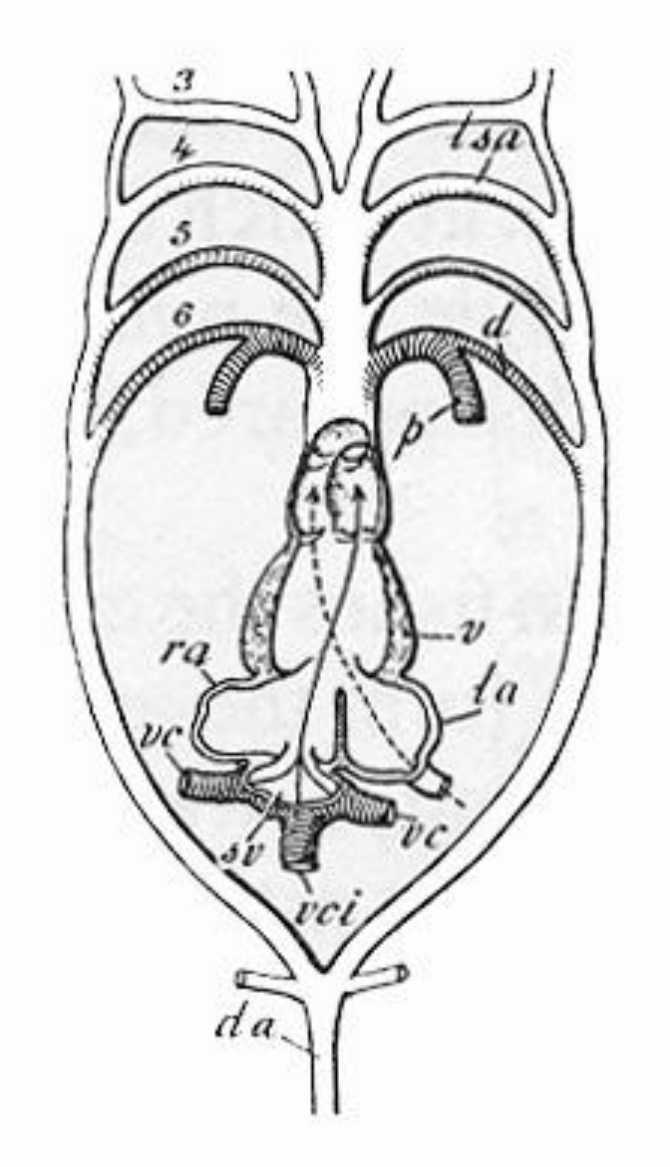

Aortic Arch Pattern of an Amphibian (Ventral Aspect)

Draw Amphibian, Ventral Aspect here:

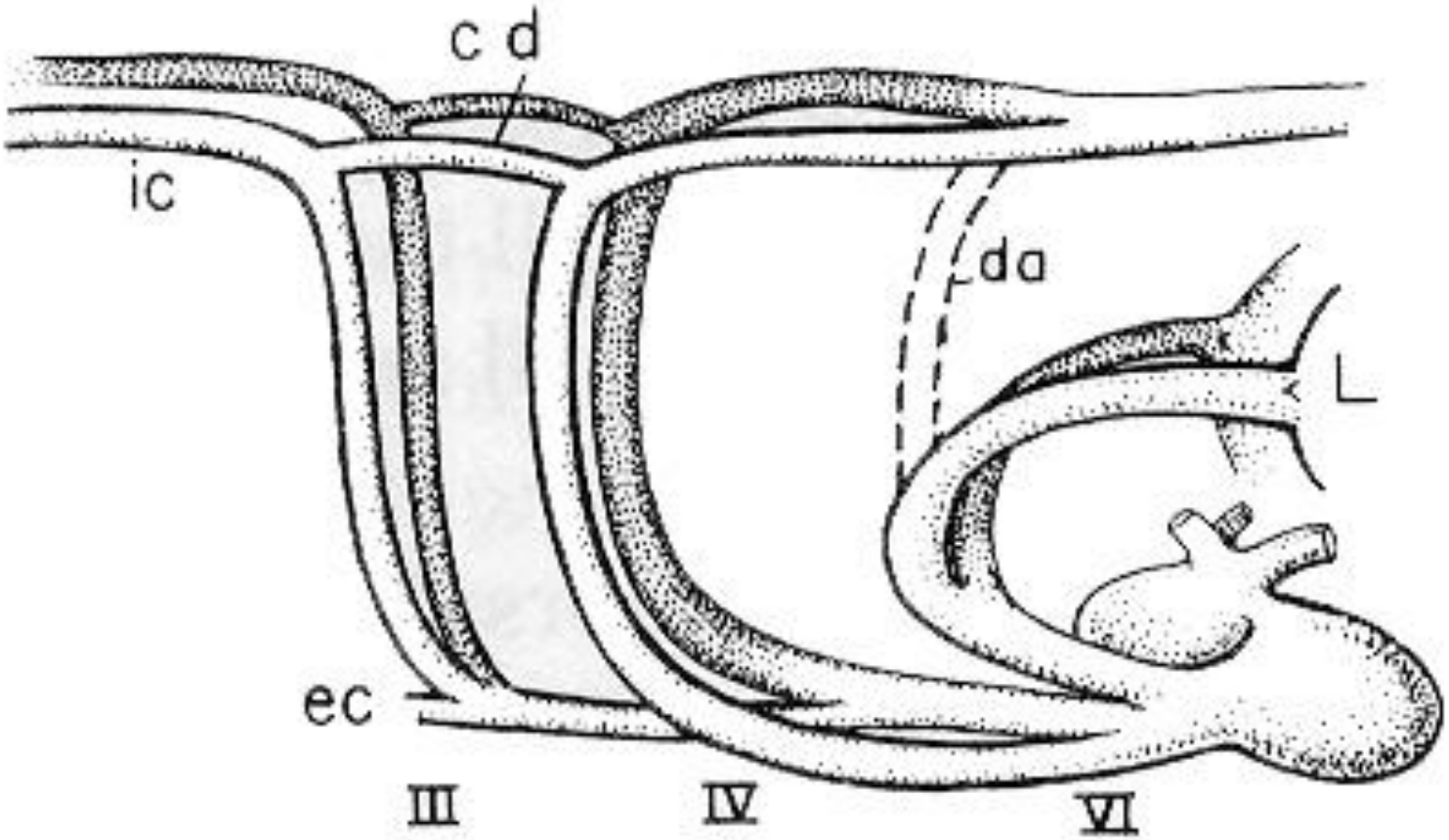

Aortic Arch Pattern of a Reptile (Lateral Aspect)

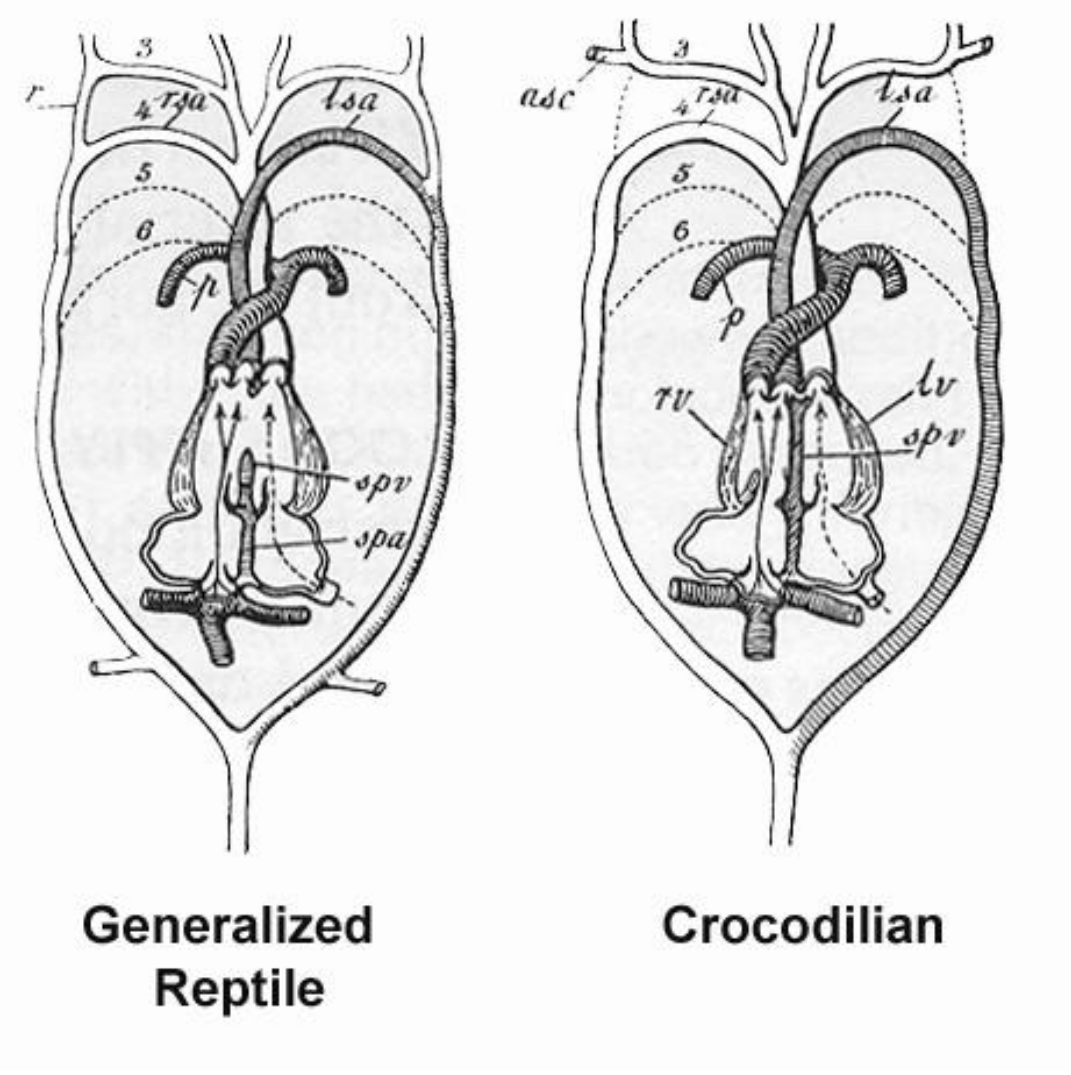

Aortic Arch Pattern of Two Reptiles (Ventral Aspect)

Draw Reptile, Ventral Aspect here:

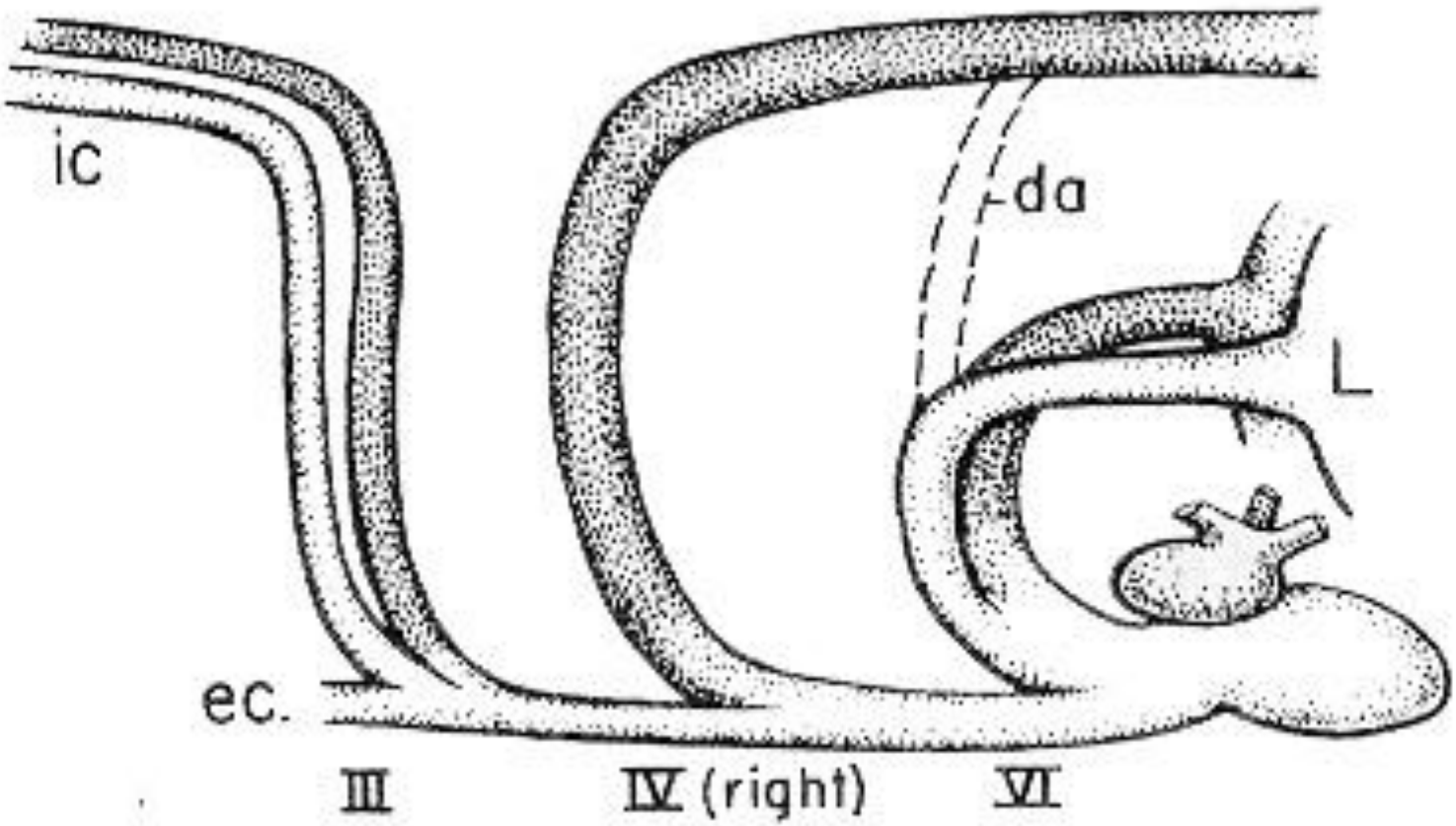

Aortic Arch Pattern of a Bird (Lateral Aspect)

Draw Bird, Ventral Aspect here:

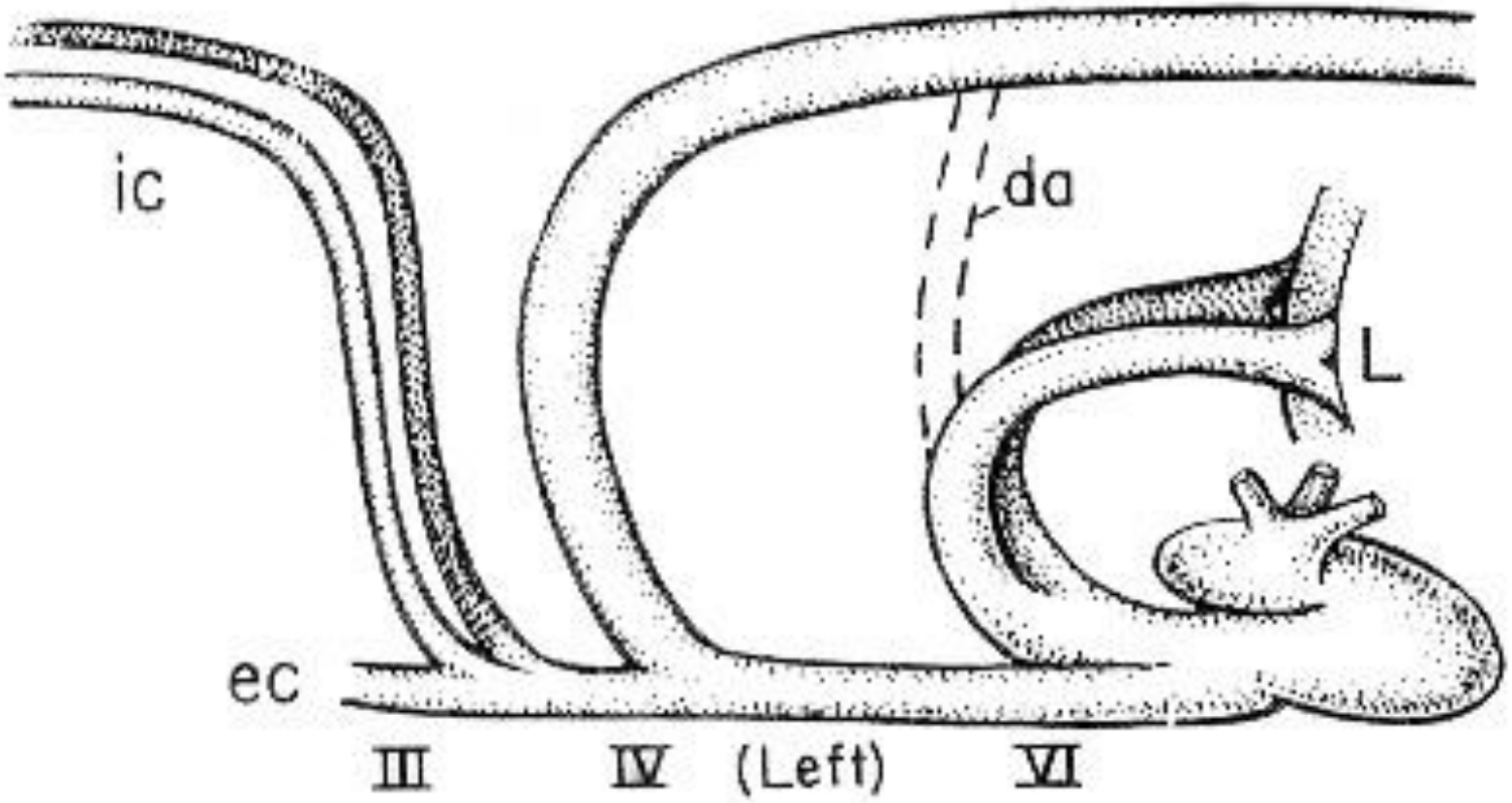

Aortic Arch Pattern of a Mammal (Lateral Aspect)

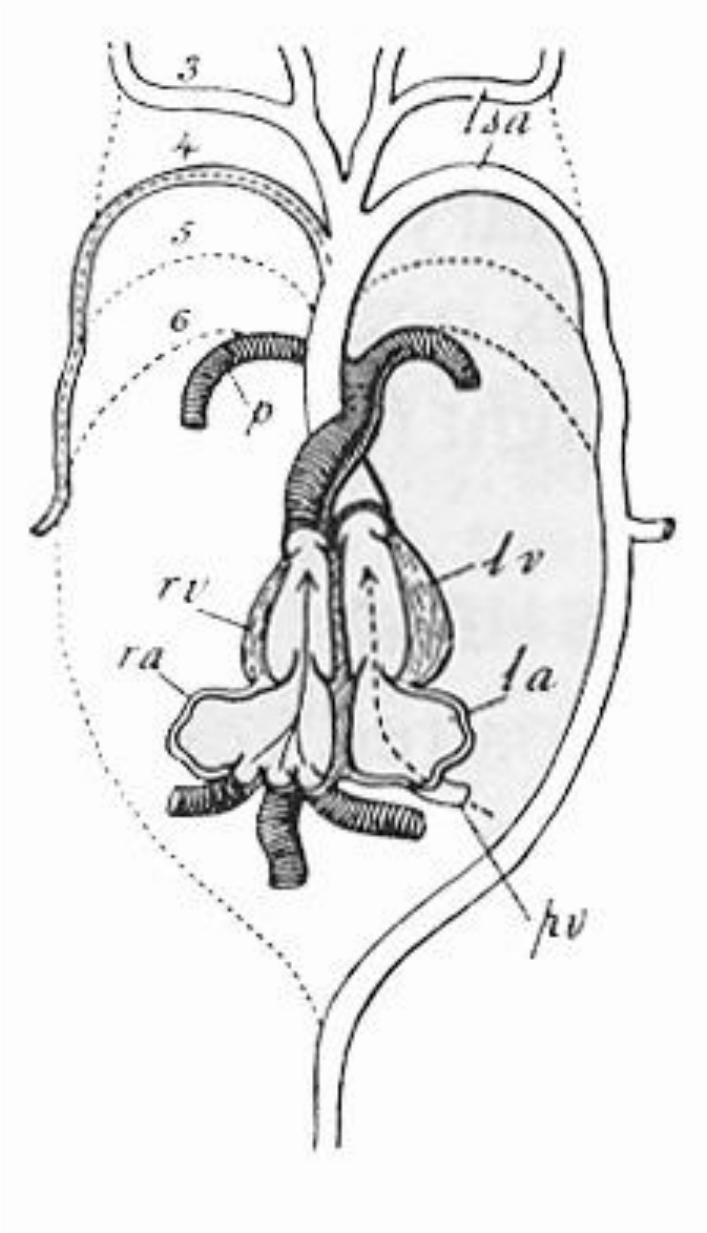

Aortic Arch Pattern of a Mammal (Ventral Aspect)

Draw Mammal, Ventral Aspect here:

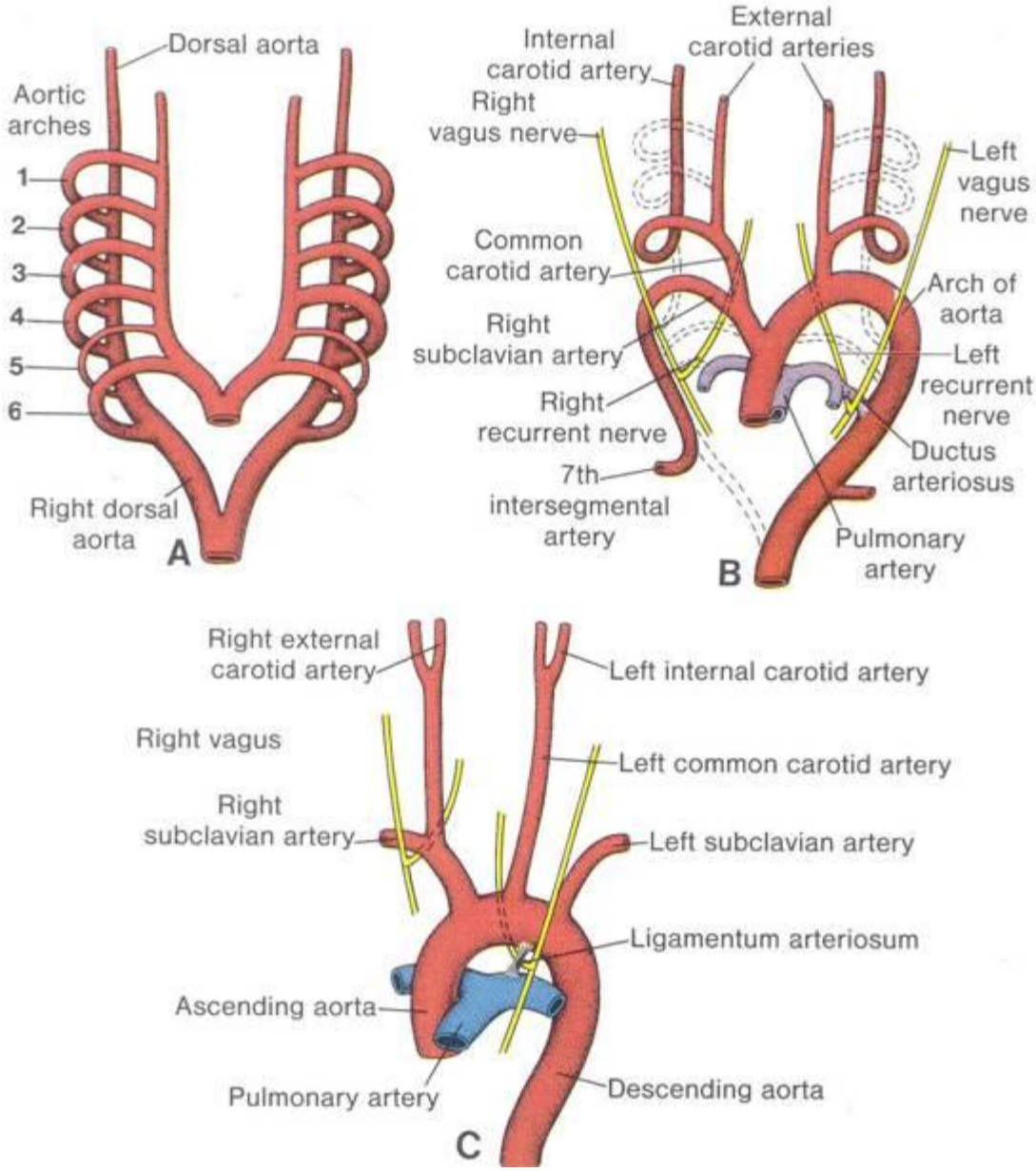
Dorsal aorta
Aortic arches
1
2
3
4
5
6
Right dorsal aorta
A
Internal carotid artery
External carotid arteries
Right vagus nerve
Left vagus nerve
Common carotid artery
Arch of aorta
Right subclavian artery
Left recurrent nerve
Right recurrent nerve
Ductus arteriosus
7th intersegmental artery
Pulmonary artery
B
Right external carotid artery
Left internal carotid artery
Right vagus
Left common carotid artery
Right subclavian artery
Left subclavian artery
Ligamentum arteriosum
Ascending aorta
Pulmonary artery
Descending aorta
C

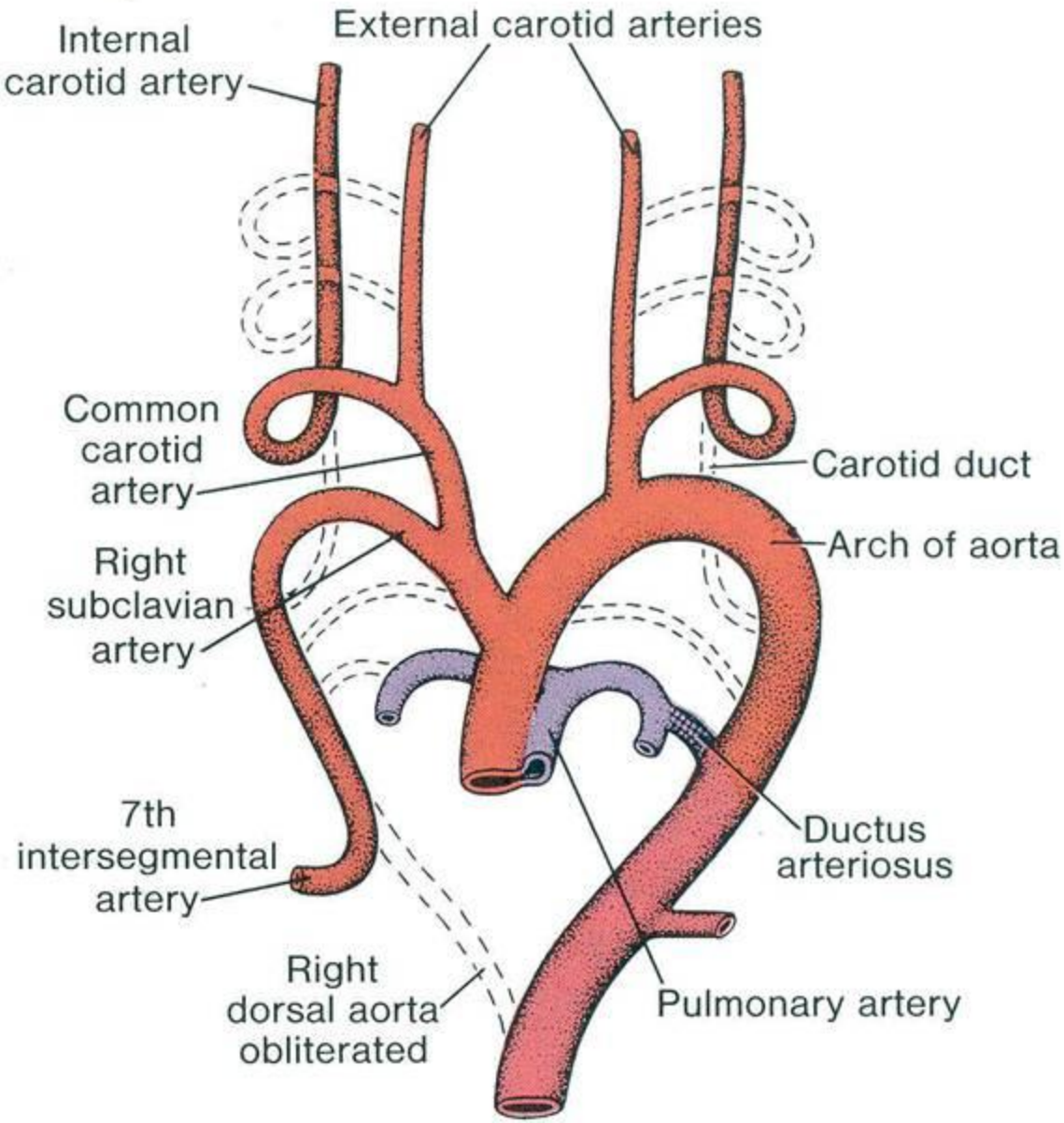
Internal carotid artery
External carotid arteries
Common carotid artery
Carotid duct
Arch of aorta
Right subclavian artery
7th intersegmental artery
Ductus arteriosus
Right dorsal aorta obliterated
Pulmonary artery

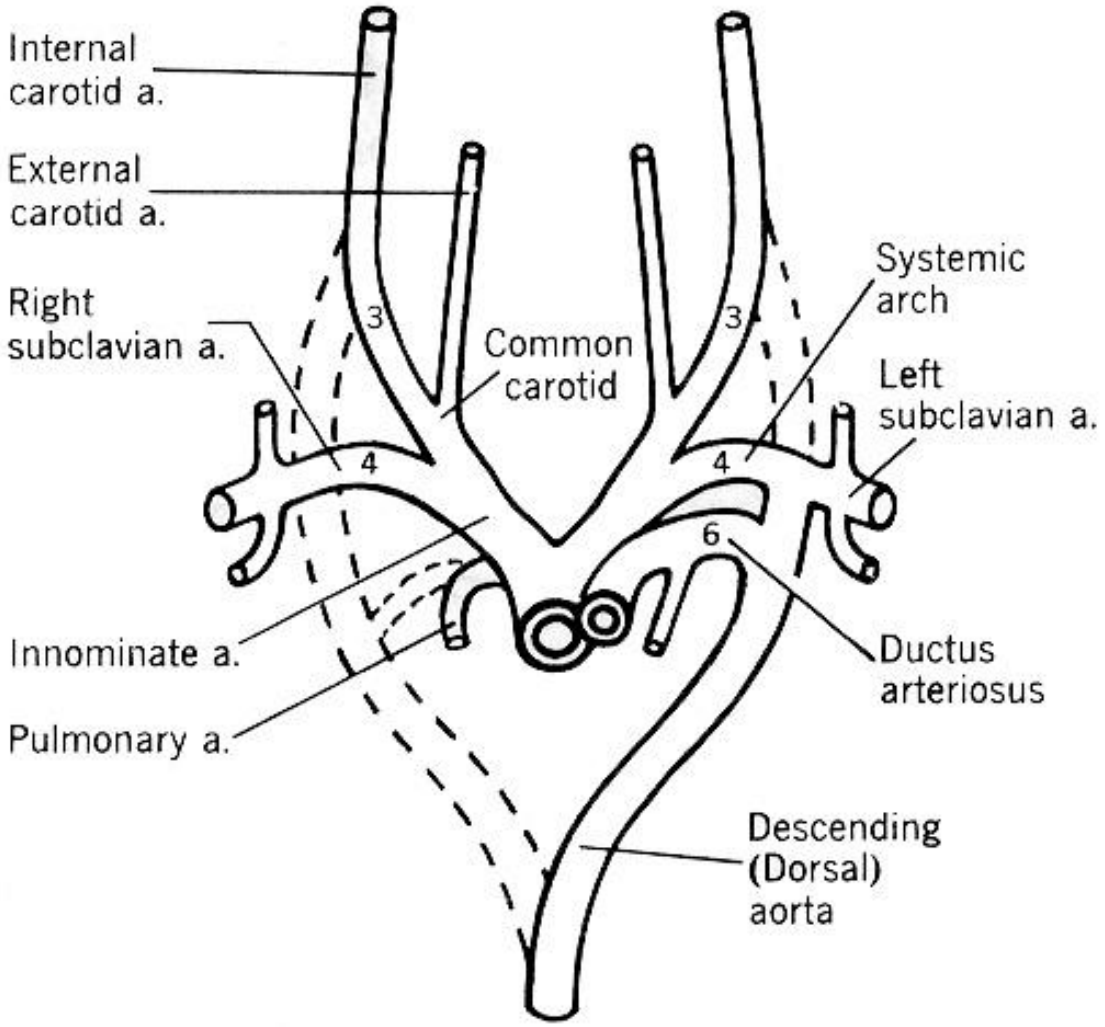

Aortic Arch Pattern of a Human (Ventral Aspect)

Aortic Arch Summary:

Arch I: Mostly disappears (a small part becomes a bit of the maxillary artery).

Aortic Arch Summary:

Arch II: DISAPPEARS

Aortic Arch Summary:

Arch III: CAROTID ARCH – becomes part of carotid arteries.

Aortic Arch Summary:

Arch IV: AORTIC ARCH -- Right side disappears. Left side becomes ARCH OF AORTA.

Aortic Arch Summary:

Arch v: DISAPPEARS

Aortic Arch Summary:

Arch VI: PULMONARY ARCH – Becomes pulmonary artery to lungs.

Great Veins of the Thorax

1. Venous blood dumps in the right atrium of the heart.
   (a) Blood from the cranial region enters via superior vena cava
   (b) Body blood enters via inferior vena cava

2. Inferior vena cava - passes through the diaphragm after receiving blood from the abdominal gut.

3. Superior vena cave & its 3 tributaries:
   (a) Azygous vein
   (b) Right brachiocephalic vein
   (c) Left brachiocephalic vein

Superior
Vena Cava

Azygous
Vein

Hemiazygous
Vein

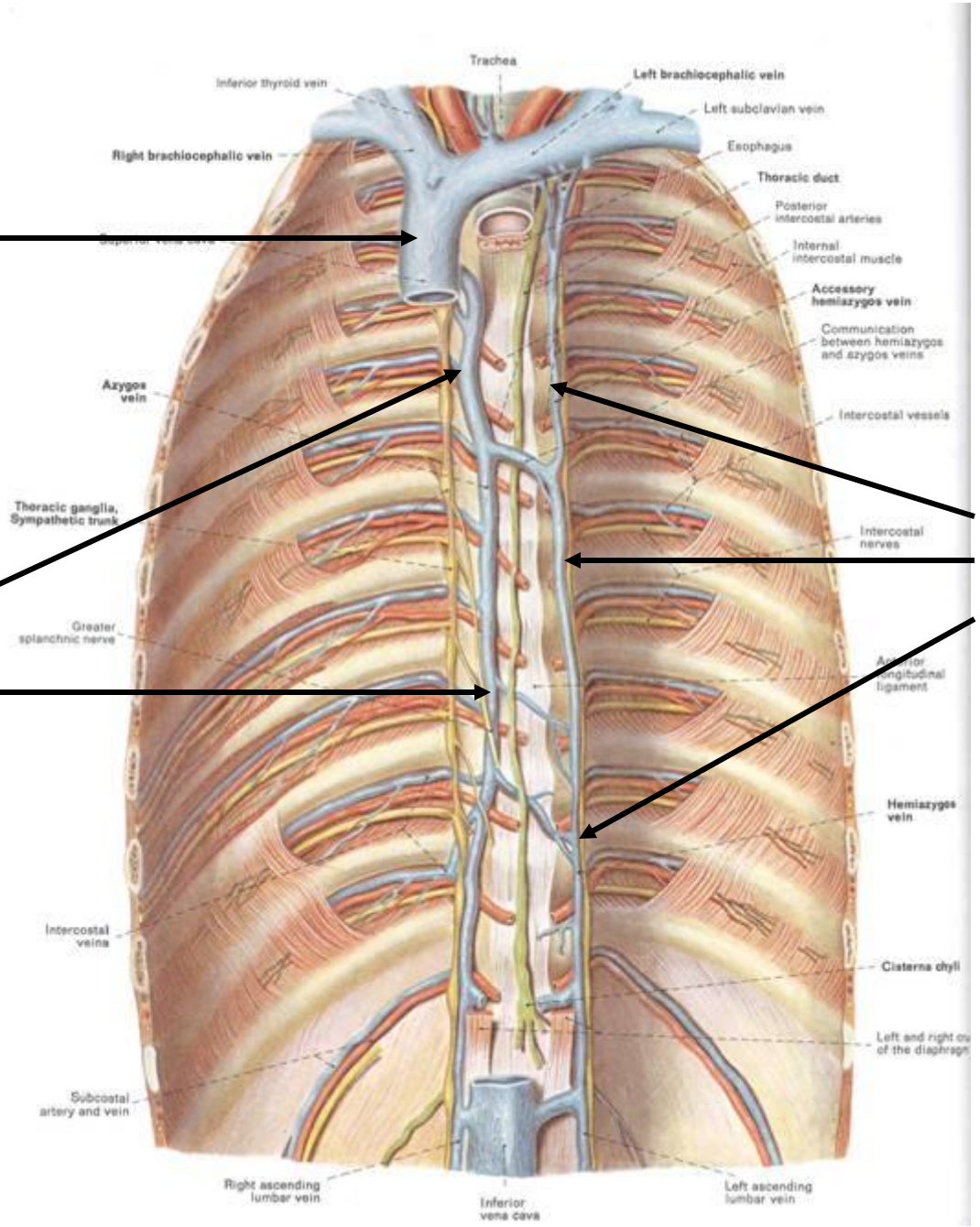

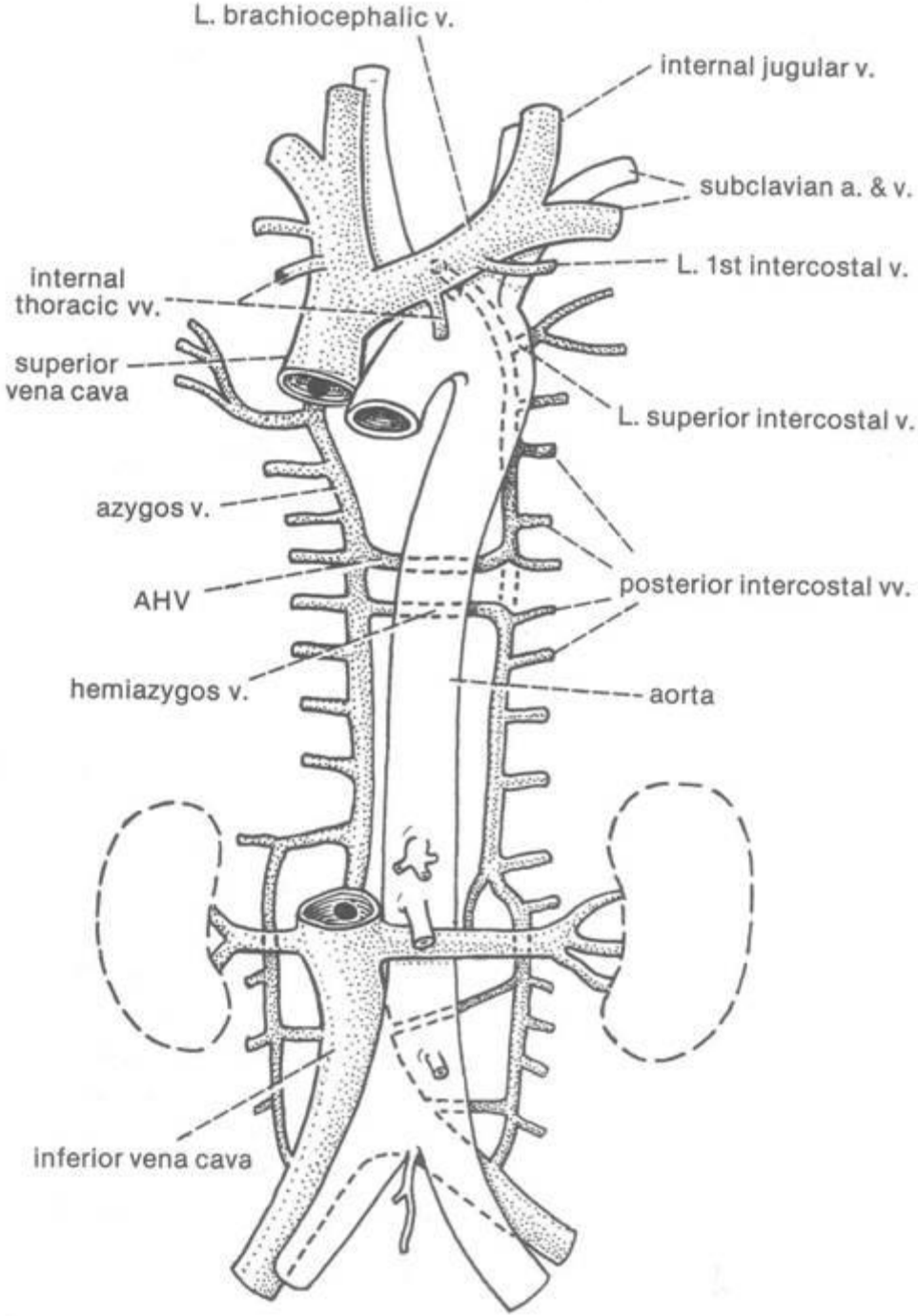
L. brachiocephalic v.
internal jugular v.
subclavian a. & v.
L. 1st intercostal v.
internal thoracic vv.
superior vena cava
L. superior intercostal v.
azygos v.
AHV
posterior intercostal vv.
hemiazygos v.
aorta
inferior vena cava

Further Development:

Excretory and Reproductive Systems

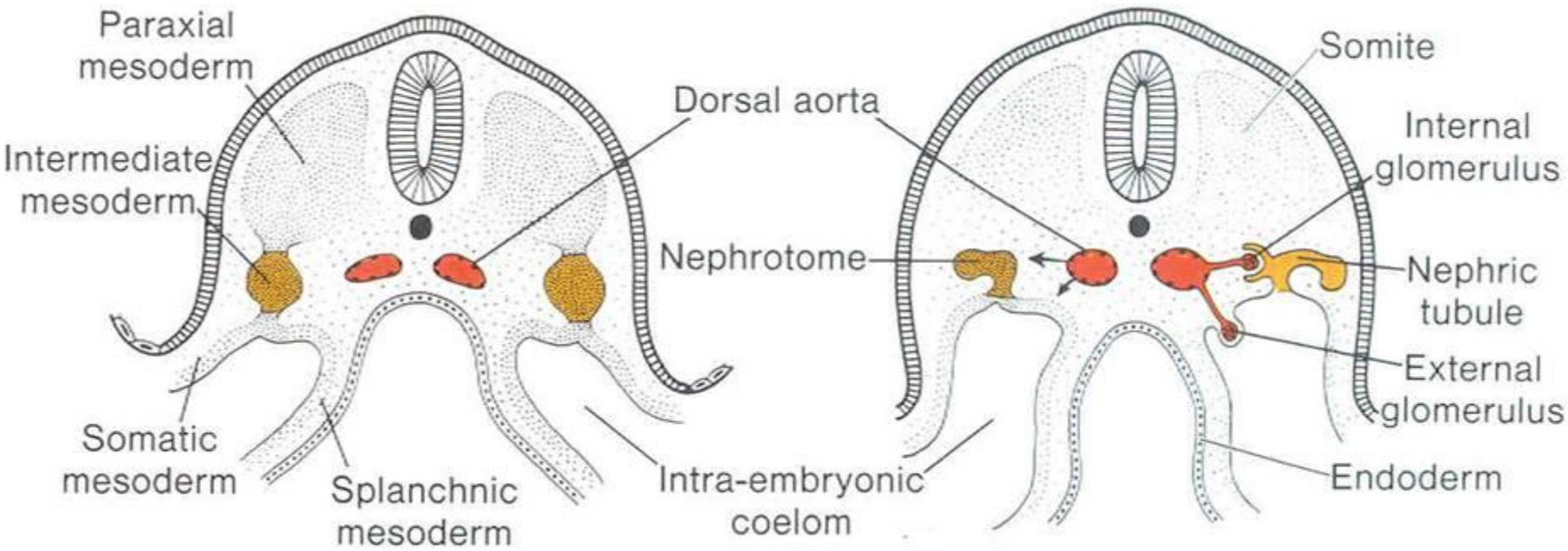
Paraxial mesoderm
Intermediate mesoderm
Dorsal aorta
Nephrotome
Somatic mesoderm
Splanchnic mesoderm
Intra-embryonic coelom
Somite
Internal glomerulus
Nephric tubule
External glomerulus
Endoderm

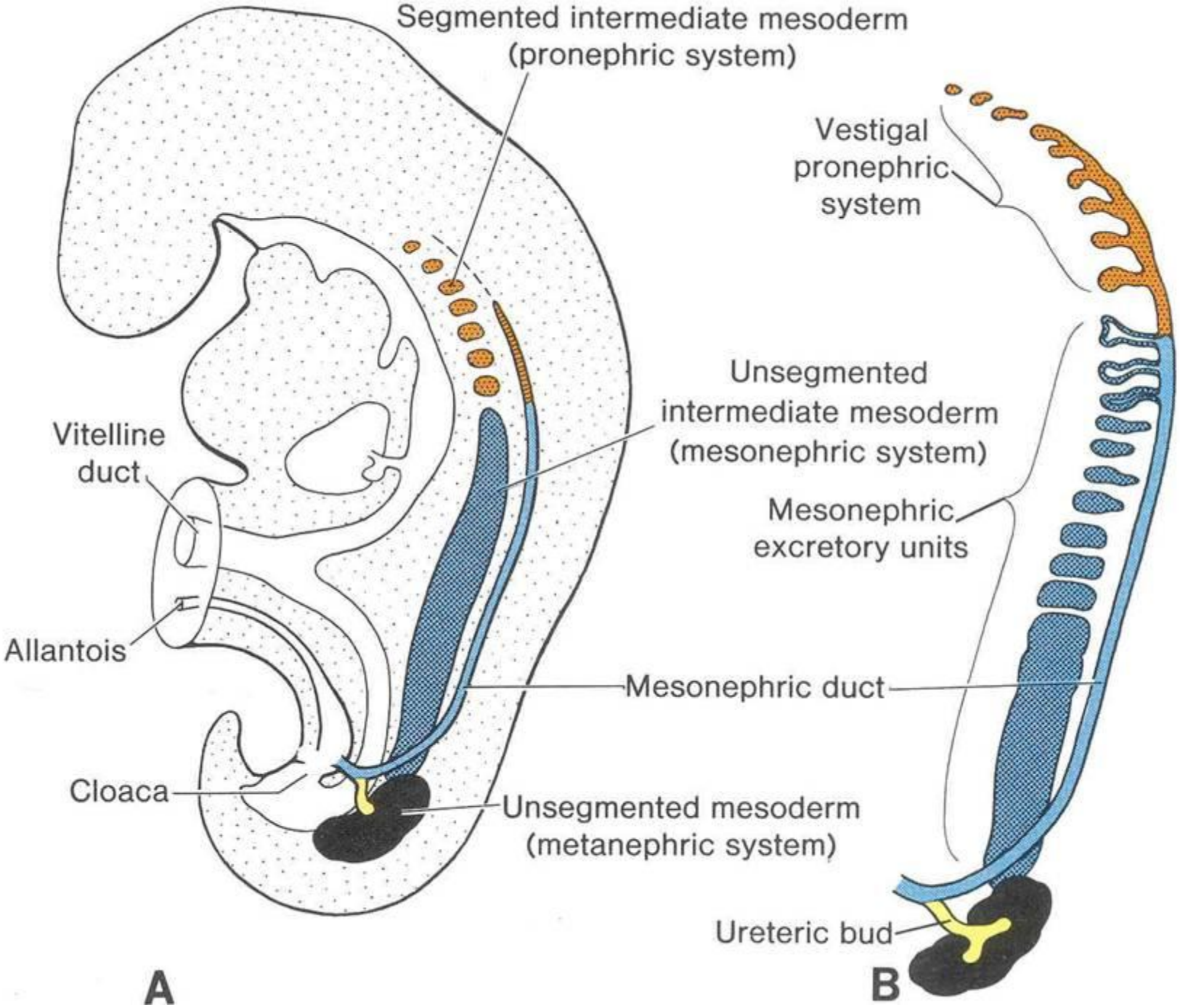
Segmented intermediate mesoderm
(pronephric system)
Vestigal
pronephric
system
Unsegmented
intermediate mesoderm
(mesonephric system)
Vitelline
duct
Mesonephric
excretory units
Allantois
Mesonephric duct
Cloaca
Unsegmented mesoderm
(metanephric system)
Ureteric bud
A
B

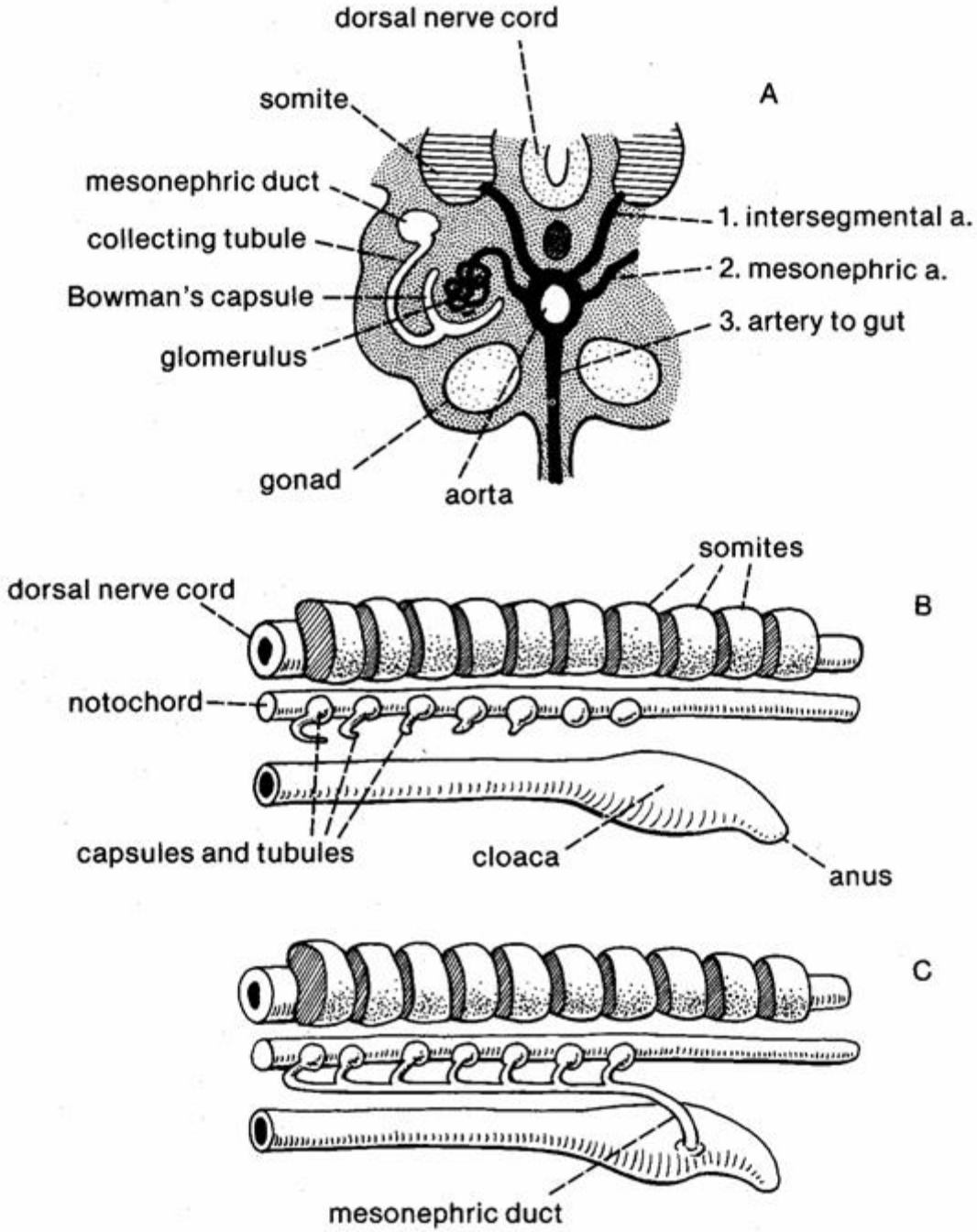
dorsal nerve cord
A
somite
mesonephric duct
collecting tubule
Bowman's capsule
glomerulus
1. intersegmental a.
2. mesonephric a.
3. artery to gut
gonad
aorta
somites
dorsal nerve cord
B
notochord
capsules and tubules
cloaca
anus
C
mesonephric duct

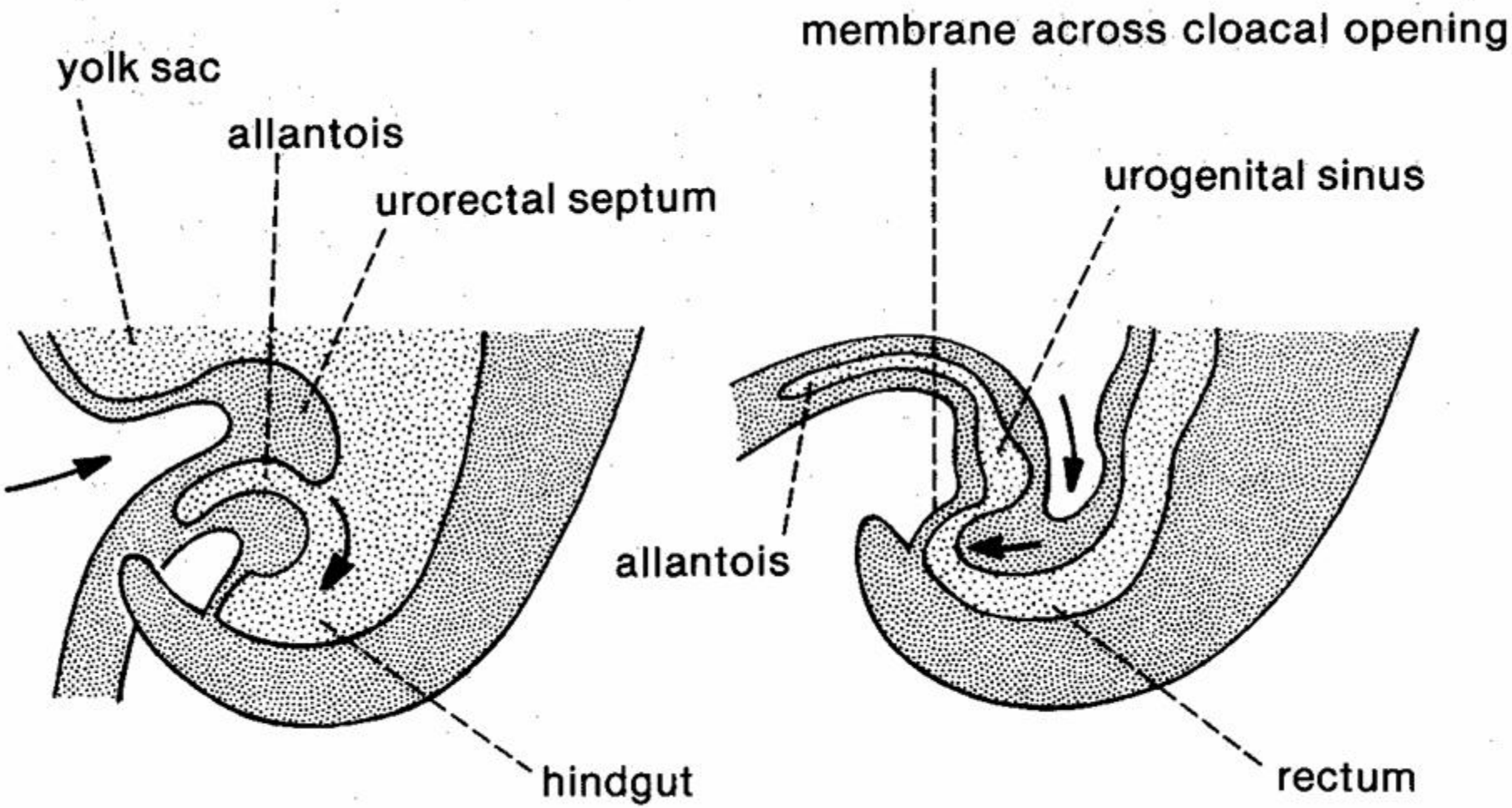
yolk sac
allantois
urorectal septum
hindgut
membrane across cloacal opening
urogenital sinus
allantois
rectum

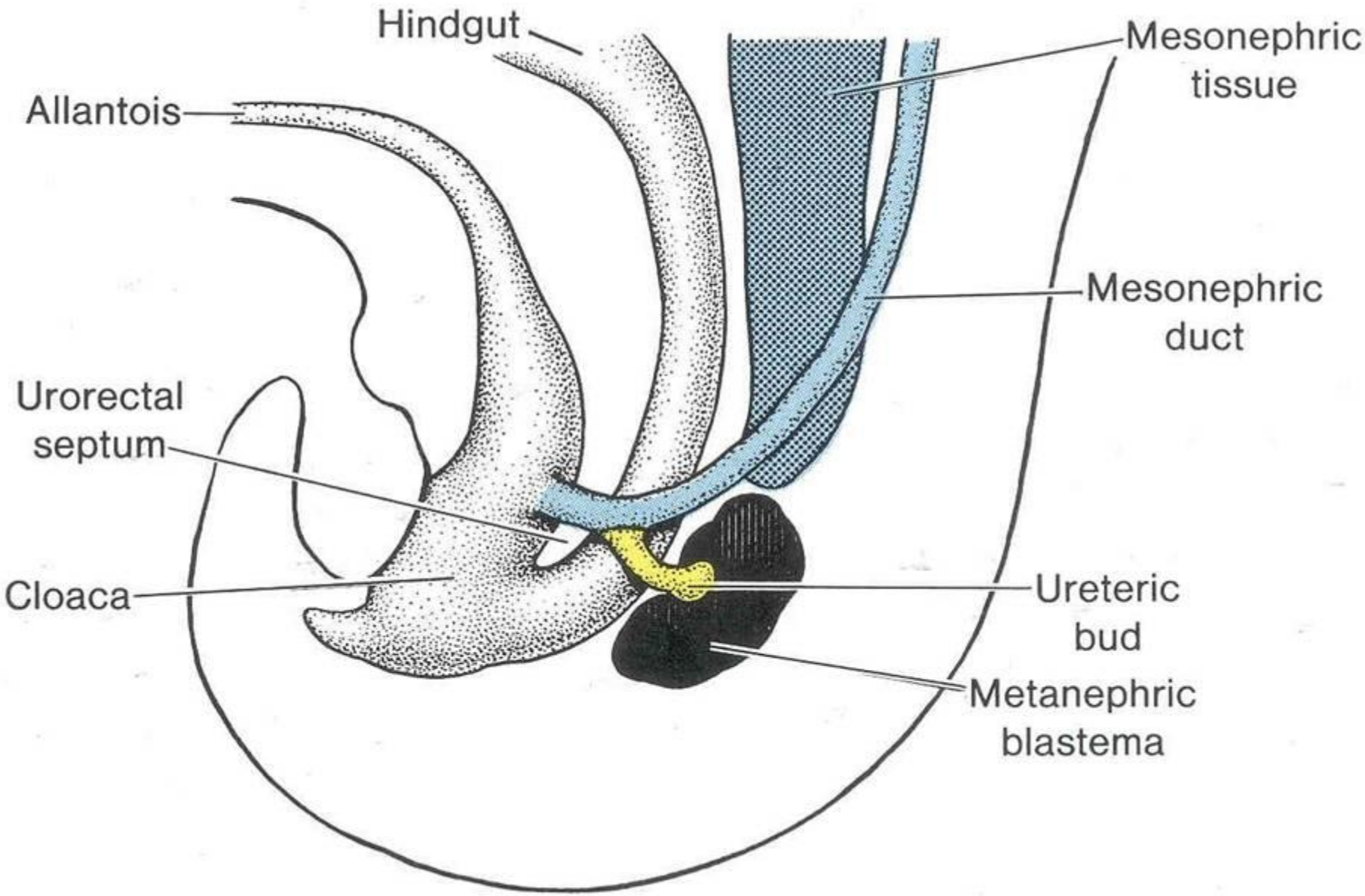
Hindgut
Mesonephric tissue
Allantois
Mesonephric duct
Urorectal septum
Cloaca
Ureteric bud
Metanephric blastema

Do your own illustration here:

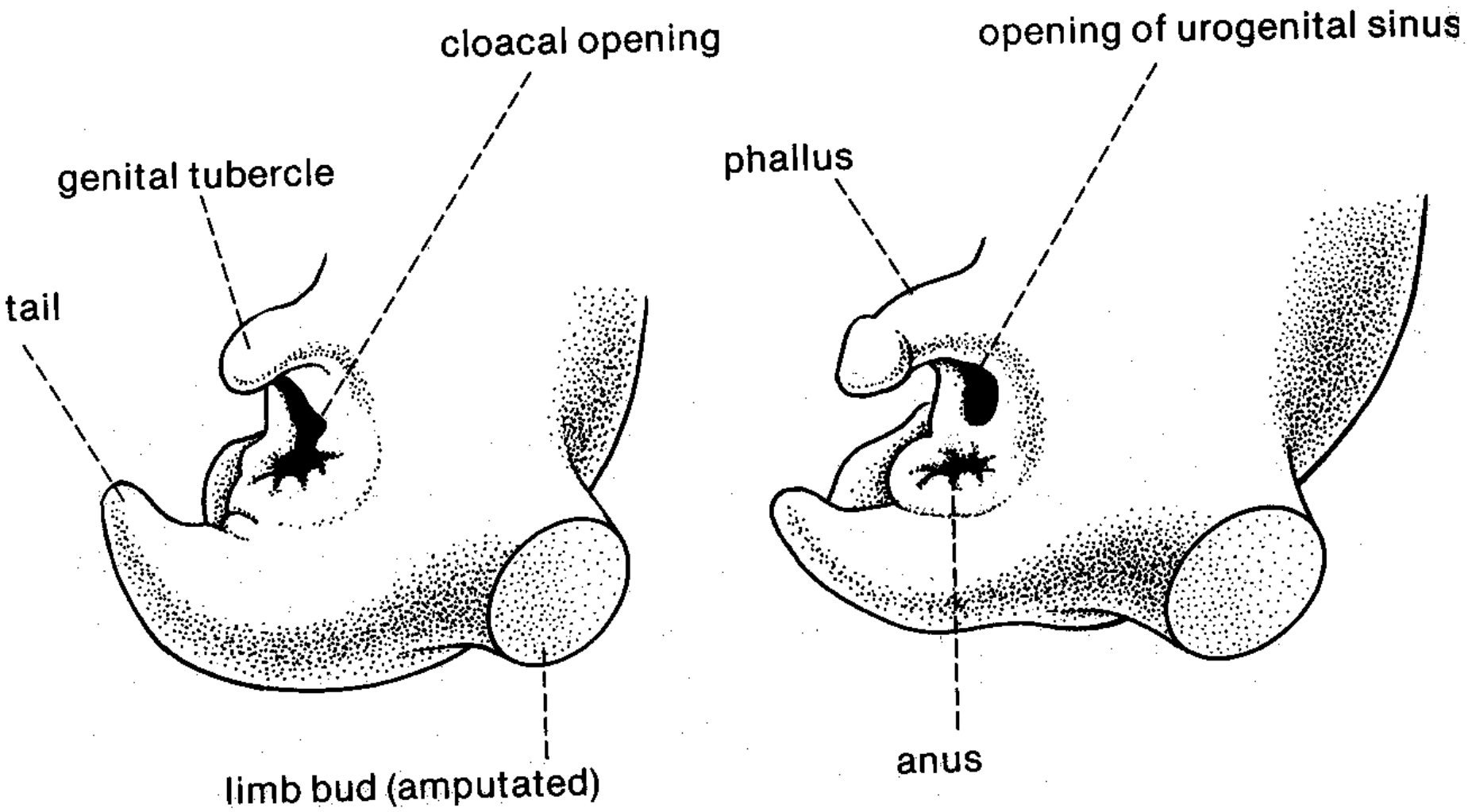
cloacal opening
genital tubercle
tail
limb bud (amputated)
opening of urogenital sinus
phallus
anus

Development of urogenital organs/RELATIONSHIP TO ADULT MORPHOLOGY

"MARS"

Former kidney duct become ductus deferns, epididymous, retains connection to bladder

"VENUS"

New tubes fuse at midline to become uterine tubes, uterus, superior 2/3 vagina

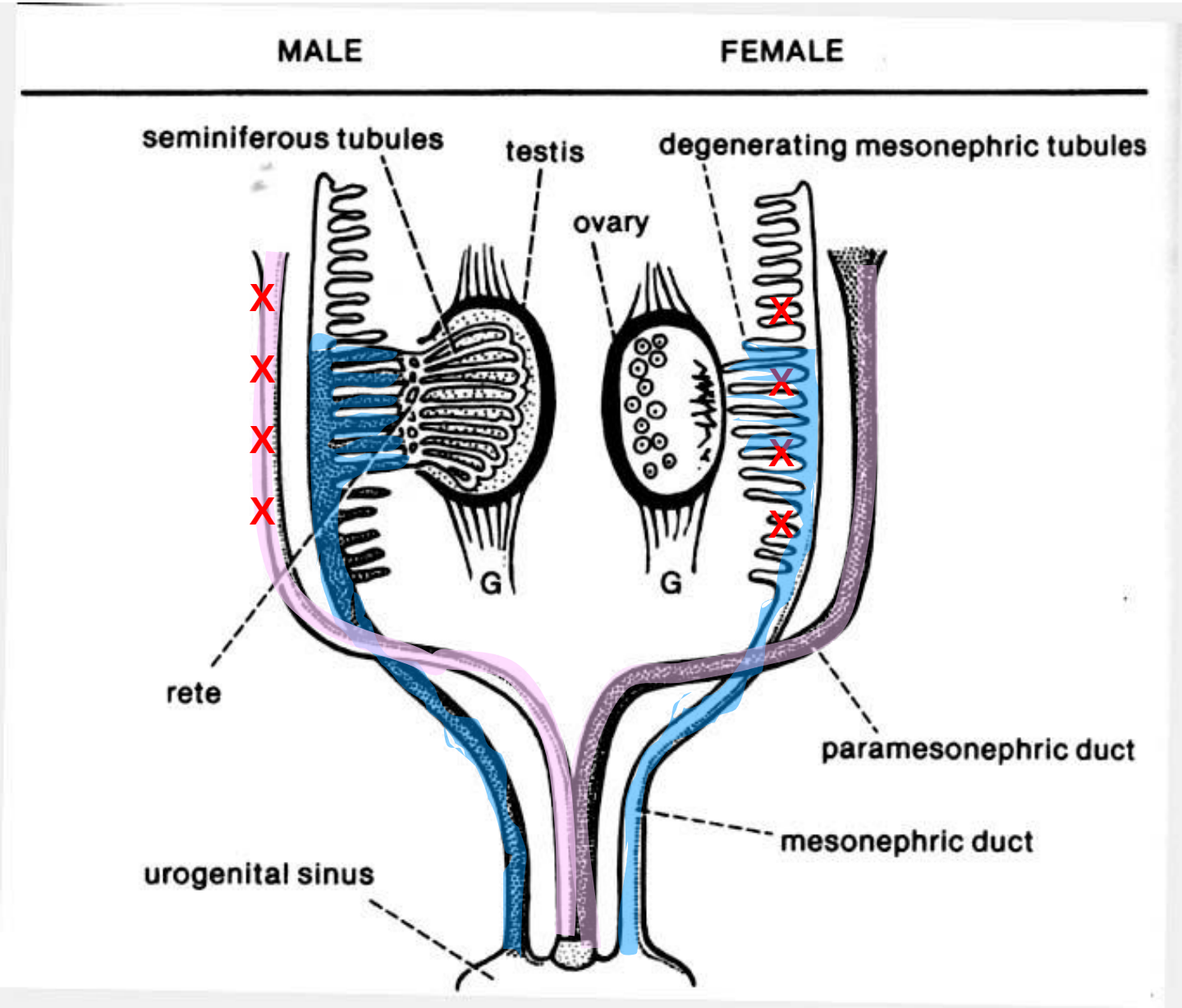

ERECTILE TISSUE IN THE MALE

Males have three columns of erectile tissue.

- **Right and left bulbs fuse in the midline to form the CORPORA SPONGIOSUM – surrounds the urethra.**
- **Urethra emerges out of tip of enlarged genital tubercle – the GLANS OF THE PENIS.**
- **At its tip is the bulbous dilation that is the GLANS OF THE PENIS.**

- **Right and left crura remain independent and form the paired CORPORA CAVERNOSA.**
- **Right and left sides are bound to one another by TUNICA ALBUGINEA.**

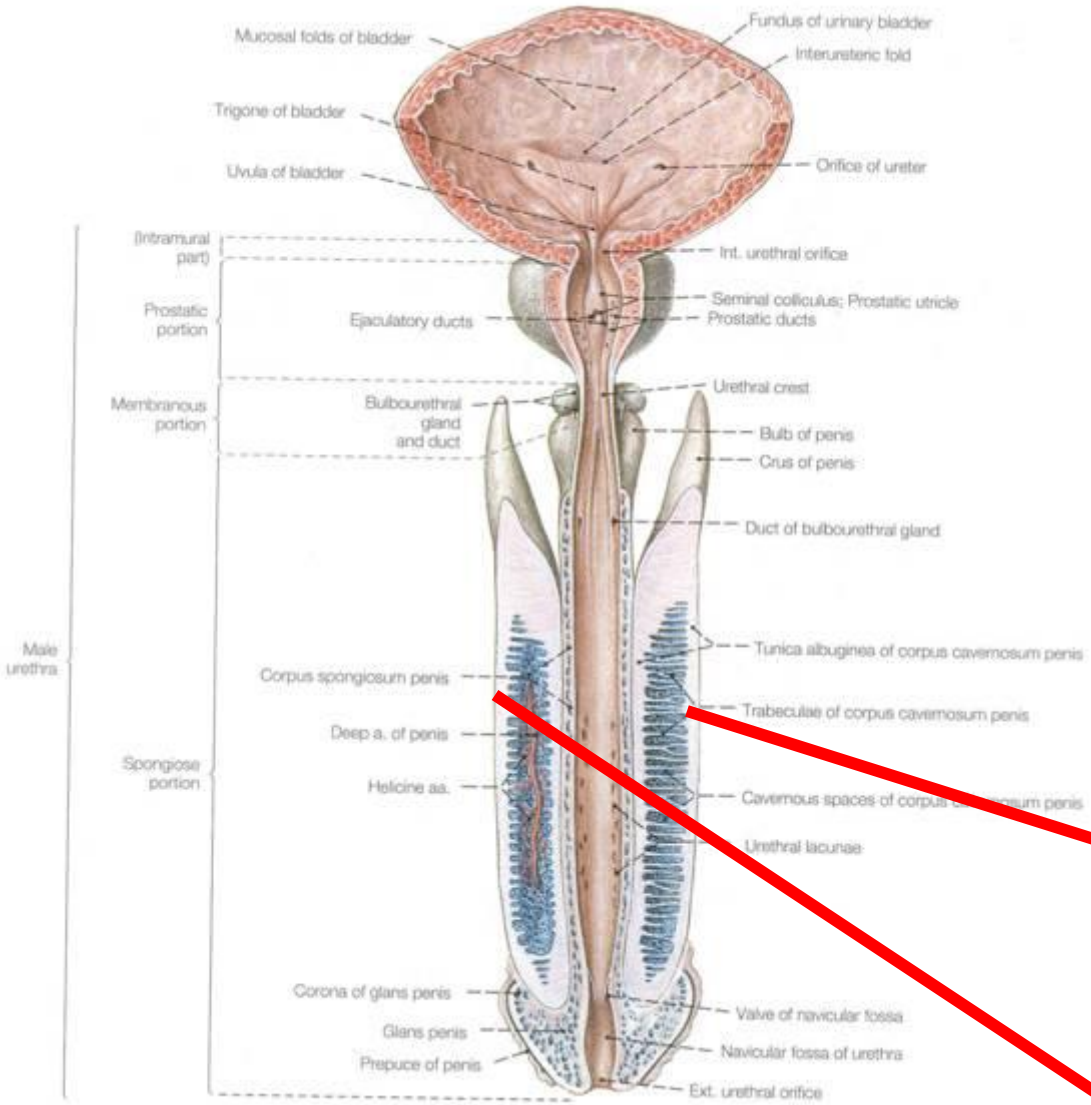
Mucosal folds of bladder
Fundus of urinary bladder
Interureteric fold
Trigone of bladder
Uvula of bladder
Orifice of ureter
(Intramural part)
Int. urethral orifice
Prostatic portion
Seminal colliculus; Prostatic utricle
Ejaculatory ducts
Prostatic ducts
Urethral crest
Membranous portion
Bulbourethral gland and duct
Bulb of penis
Crus of penis
Duct of bulbourethral gland
Male urethra
Tunica albuginea of corpus cavernosum penis
Corpus spongiosum penis
Trabeculae of corpus cavernosum penis
Deep a. of penis
Spongiose portion
Helicine aa.
Cavernous spaces of corpus
Urethral lacunae
Corona of glans penis
Valve of navicular fossa
Glans penis
Navicular fossa of urethra
Prepuce of penis
Ext. urethral orifice

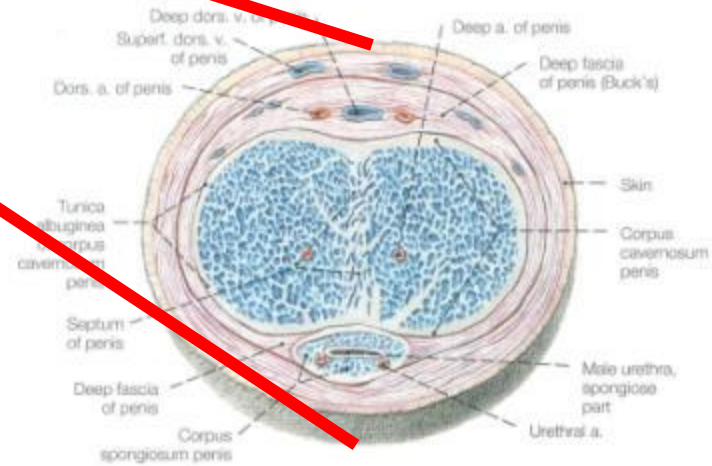
Superf. dors. v. of penis
Deep a. of penis
Deep fascia of penis (Buck's)
Dors. a. of penis
Skin
Tunica
Corpus cavernosum penis
Septum of penis
Male urethra, spongiose part
Deep fascia of penis
Urethral a.
Corpus spongiosum penis

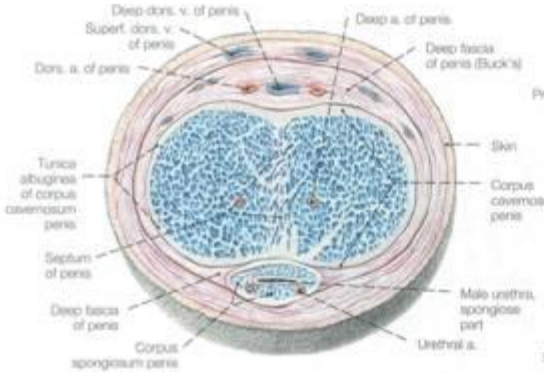

Fig. 1092 The penis, cross section, ventral view. The level of the section is shown in Fig. 1096. Note the incomplete separation of the two corpora cavernosa by the septum of the penis.

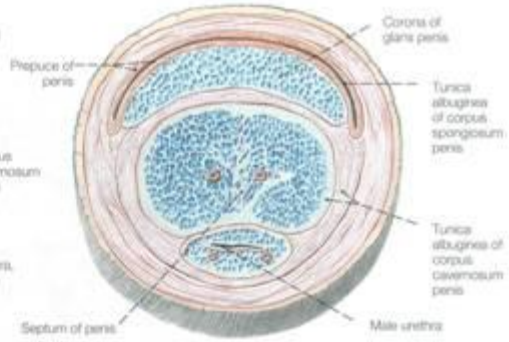

Fig. 1093 The penis, cross section, ventral view. The level of the section is shown in Fig. 1096.

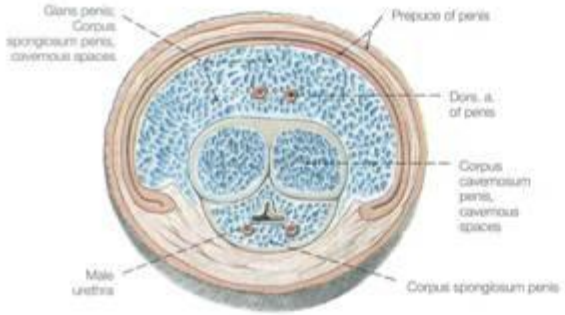

Fig. 1094 The penis, cross section, ventral view. The level of the section is shown in Fig. 1096.

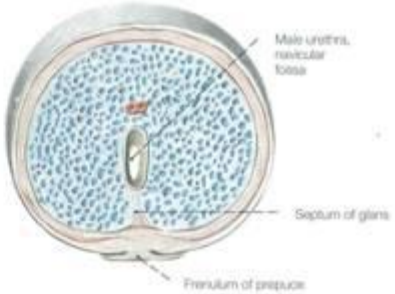

Fig. 1095 The glans penis, cross section, ventral view. The level of the section is shown in Fig. 1096.

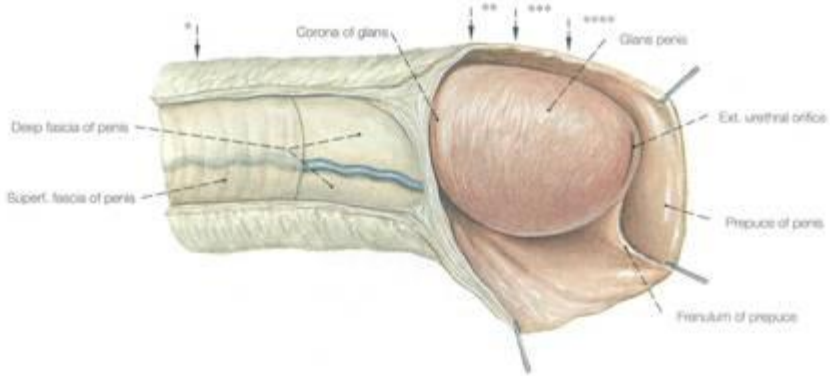

Fig. 1096 The penis with glans and prepuce, lateral view. The skin and superficial fascia of the penis have been removed layer-by-layer.

* Level of section of Fig. 1092
** Level of section of Fig. 1093
*** Level of section of Fig. 1094
**** Level of section of Fig. 1095

ERECTILE TISSUE IN THE FEMALE

- Erectile tissue is present, but bulbs do not fuse in midline and do not enlarge as much.
- They form separate masses of erectile tissue on either side of the vginal opening - the BULBS OF THE VESTIBULE, which become the LABIA MINORA (singular, MINORUM)
- As a result, the female urethra cannot be enclosed in the midline (as in the corpora spongiosa of the male)
- The tip end if the midline columns is the CLITORIS.
- Similarly sensitive to glans of male.

Clitoris

Labia majorum

Labia minorum